OBSERVATION

Trichorhinophalangeal Syndrome Type I

Clinical and Molecular Characterization of 3 Members of a Family and 1 Sporadic Case

Cornelia Sabine Seitz, MD; Hermann-Josef Lüdecke, PhD; Nicola Wagner, MD; Eva-Bettina Bröcker, MD; Henning Hamm, MD

Background: Trichorhinophalangeal syndrome type I (TRPS I) is a rare autosomal dominant disorder clinically characterized by sparse and slow-growing hair, pear-shaped nose, elongated philtrum, thin upper lip, and bone deformities, in particular, cone-shaped epiphyses of the phalanges. Very recently, the responsible gene *TRPS1* has been cloned on human chromosome 8q24.

Observation: We describe a mother and her 2 daughters and a female patient with a sporadic case of TRPS I. In the familial case, mutation analysis showed an insertional mutation at position 2480 of the *TRPS1* gene leading to a premature translational stop. Careful clinical examination showed craniofacial and radiologic features typical of TRPS I, including short stature, in all 3 affected individuals. Additionally, they presented with a receded triangular medio-occipital hairline, which has not been described in TRPS I so far. In the sporadic case, we identified a single base deletion at position 2110 of the *TRPS1* gene leading to frameshift and premature translational stop at codon 766. The patient presented with the typical TRPS I phenotype but was of normal stature.

Conclusions: The TRPS I is characterized by variable clinical expression of the triad of hair, craniofacial, and skeletal abnormalities. New genetic approaches, including mutation analysis, now allow identification of carriers of the *TRPS1* gene mutations.

Arch Dermatol. 2001;137:1437-1442

From the Department of Dermatology, University of Würzburg, Würzburg, Germany (Drs Seitz, Wagner, Bröcker, and Hamm), and Institute for Human Genetics (Dr Lüdecke), University Hospital, Essen, Germany.

THE trichorhinophalangeal syndrome type I (TRPS I), first described by Giedion in 1966,[1] is an autosomal dominant disorder clinically characterized by hypotrichosis of the scalp with fine, slow-growing hair, a high frontal hairline, and rarefaction of the lateral eyebrows. Craniofacial abnormalities include pear-shaped nose, elongated philtrum, thin upper lip, and a receding chin, giving rise to a distinctive facies. In addition, patients may show brachydactyly, distention and deviation of middle phalanges, hip malformation, and short stature. Radiologic findings include cone-shaped epiphyses mainly at the bases of the middle phalanges of the hands and feet.[2] So far, in the dermatologic literature, a total of 29 cases have been reported, comprising 16 familial and 12 sporadic cases.

Recently, the responsible gene was identified and named *TRPS1*.[3] It encodes a 141-kd protein with 2 potential nuclear localization signals and 9 zinc finger motifs. Therefore, *TRPS1* presumably acts as a transcription factor. Most patients with TRPS I have nonsense mutations in the *TRPS1* gene or a complete deletion of this gene. Interestingly, Lüdecke et al[4] found that all patients with TRPS with a severe form of brachydactyly and growth retardation, formerly described as TRPS type III,[5] have missense mutations in the DNA-binding GATA-type zinc finger of the protein. Patients with multiple cartilaginous exostoses in addition to the TRPS phenotype have TRPS type II or Langer-Giedion syndrome, a contiguous gene syndrome, in which both the *TRPS1* gene and the gene that is mutant in multiple exostosis type I (*EXT1*) are deleted.[3]

Herein, we describe 4 additional cases of TRPS I, a sporadic case in a woman and a family with the mother and her 2 daughters affected, and present 2 mutations of the *TRPS1* gene as the underlying genetic defect.

REPORT OF CASES

CASE 1

A 26-year-old woman consulted us because of slow-growing scalp hair. Since infancy her hair had never grown longer

©2001 American Medical Association. All rights reserved.
Downloaded From: http://archderm.jamanetwork.com/ on 05/19/2013

Figure 1. Typical facies with bulbous nose, long philtrum, thin upper lip, and rarefaction of lateral eyebrows (patient 1).

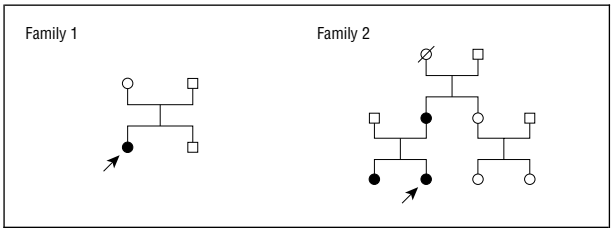

Figure 2. Pedigrees of the 2 reported families with trichorhinophalangeal syndrome type I. Filled symbols indicate affected family members; arrows, index patients.

than 10 cm. Clinical examination disclosed thin scalp hair, a nonscarring diffuse alopecia with accentuation of the frontoparietal regions, and a receding frontotemporal hairline. Rarefaction of lateral eyebrows was observed although eyelashes were normal. Axillary hair was reduced. A typical pear-shaped nose as well as a long philtrum were noticeable (**Figure 1**). Nail changes included racket nails of the third fingers. Further abnomalities included scoliosis, swelling of proximal interphalangeal joints of both hands, radial deviation of the fourth and fifth phalanges of both hands, and hypermotility of the metacarpophalangeal joints of both hands. Her height was 168 cm. There was no obvious intellectual impairment. Neither her parents, whom we examined personally, nor her younger brother were affected (**Figure 2**).

Radiologic examination showed cone-shaped and widened epiphyses of the second to fifth proximal phalanges of both hands. In the left knee, a loose body was detected. Radiographs of thorax, shoulders, elbows, and hips disclosed no abnormalities.

Figure 3. Thin scalp hairs, mild diffuse alopecia, and receding frontoparietal hairline (patient 3).

CASE 2

A 22-year-old woman with short stature (148 cm) presented with diffuse alopecia of the scalp, receded frontotemporal hairline, and rarefaction of lateral eyebrows and eyelashes of the lower eyelids. The medial part of the occipital hairline was also receding in a triangular shape. The patient complained about slow scalp hair growth of about 1.5 cm in 4 months, evidenced by a recent hair coloring and maximal scalp hair length of about 8 cm. Further physical examination was remarkable for a bulbous nose, thin upper lip, elongated philtrum, racket thumbnails, short fingers with ulnar deviation of index and ring fingers of both hands, and partial cutaneous syndactyly of the second and third toes of the left foot and the third and fourth toes of the right foot. She had undergone reconstructive orthopedic surgery of the left hand and left ankle. Radiologic examination showed cone-shaped epiphyses of the second to fifth proximal phalanges of both hands and the first to fifth of both feet. Furthermore, a small exostosis of the medial femur condylus was observed. The patient had had insulin-dependent diabetes since age 15 years.

CASE 3

The 25-year-old sister of patient 2 showed a pear-shaped nose, a receding frontoparietal (**Figure 3**) and triangular medio-occipital hairline, mild diffuse alopecia of the scalp, rarefaction of the lateral eyebrows, and virtual absence of the eyelashes of the lower eyelids. Deceleration of scalp hair growth was denied. She presented with brachydactyly, radial deviation of the index fingers of both hands and of the ring finger of the left hand, racket nails of the big toes, and syndactyly of the second and third toes of both feet. Her height was 146 cm. No radiologic examination was performed.

CASE 4

The 51-year-old mother of patients 2 and 3 presented with a less conspicuous nose, protruding ears, a long philtrum, discrete diffuse alopecia of the scalp with fine hair, a receding triangular medio-occipital hairline

©2001 American Medical Association. All rights reserved.
Downloaded From: http://archderm.jamanetwork.com/ on 05/19/2013

Figure 4. Receding medio-occipital hairline of triangular shape (patient 4).

Figure 5. Brachydactyly and lateral deviation of some fingers despite several reconstructive orthopedic surgeries (patient 4).

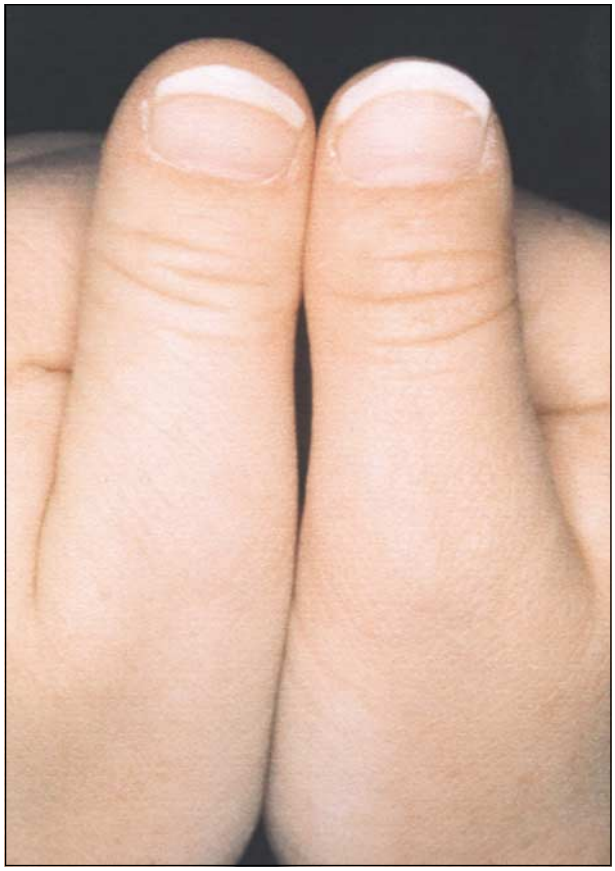

Figure 6. Bilateral racket thumbnails (patient 4).

(**Figure 4**), and rarefaction of lateral eyebrows and eyelashes. She was 152 cm tall and showed brachydactyly of both hands (**Figure 5**) with racket thumbnails (**Figure 6**) and partial syndactyly of the second and third toes of both feet. At age 16 years, she had undergone several orthopedic surgeries of her phalanges of the left and right hands. Radiologic examination showed cone-shaped epiphyses of the proximal phalanges of the second to fifth fingers of both hands (**Figure 7**), brachymetatarsia, and cone-shaped epiphyses of the first to fifth metatarsals of both feet. Additional findings were gonarthrosis, coxarthrosis, and arthrosis of the trapezoid-metacarpal joints. Results of radiographs of elbows and shoulders were normal.

RESULTS

LIGHT MICROSCOPY OF HAIR SHAFTS

Multiple hair shafts from different sites of the scalp of all patients were embedded in mounting media (Vitro-Clud; Langenbrinck Corp, Emmendingen, Germany) and examined by light and polarizing microscopy. The shafts showed reduced diameters and a high proportion of tapered distal tips typical of uncut hair (**Figure 8**). In addition, slight torsions of some hairs along the longitudinal axis were present in cases 1 and 4. Structural defects of the shafts as signs of increased fragility or breakage were lacking. Polarizing microscopy showed normal birefringence of the shafts.

HISTOLOGIC EXAMINATION OF SCALP BIOPSY SPECIMENS

Patients 1, 2, and 4 agreed to undergo temporal scalp biopsy and gave written informed consent. Biopsy specimens were divided for transverse and vertical sections[6] and were routinely processed. In all specimens, the number of hair follicles was slightly reduced, with most bulbs anchoring in the subcutaneous fat (**Figure 9**). Some anagen follicles had a somewhat smaller size, with their bulbs located at the boundary of the subcutis. The dermal papilla of the terminal hair bulbs appeared reduced in relation to the well-developed bulb epithelium (Figure 9, inset). Except for this, no structural abnormalities of the hair follicles were evident. The number of telogen and vellus hairs was not increased. There were no signs of inflammation or scarring.

MUTATION ANALYSIS

Mutation analysis was performed as previously described[3] after all individuals gave informed consent. Mutation analysis in case 1 identified a single base deletion at position 2110 of the *TRPS1* gene leading to frameshift and premature translational stop after codon 766. Analysis of the parents did not show any mutation, implying a de novo mutation in the patient.

©2001 American Medical Association. All rights reserved.
Downloaded From: http://archderm.jamanetwork.com/ on 05/19/2013

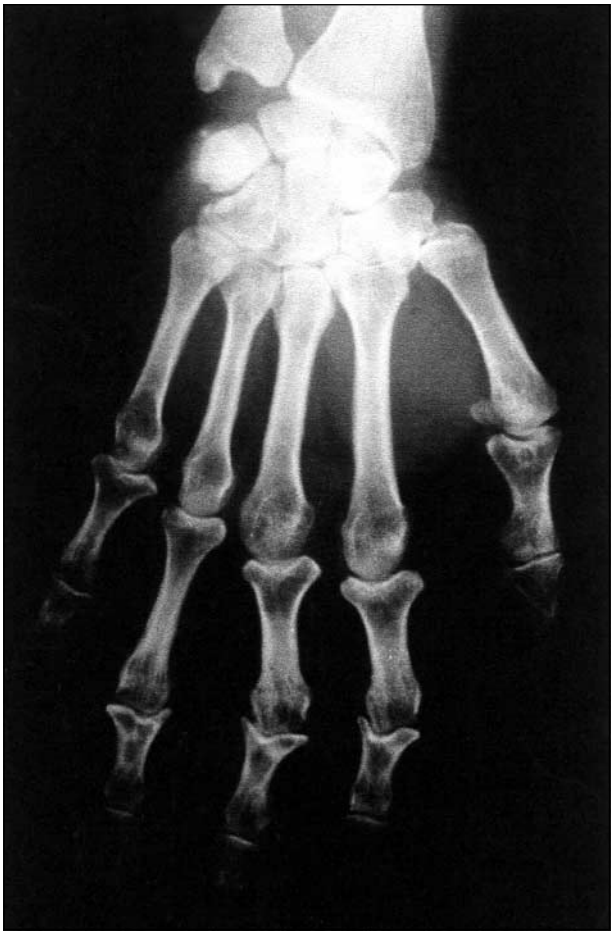

Figure 7. Corresponding radiographs of left hand with cone-shaped epiphyses of proximal phalanges (patient 4).



Figure 8. Light microscopy of hair shafts showing a reduction in diameter (48 μm) and identifying tapered tips (bottom) typical of uncut hair (patient 1).

All 3 family members (cases 2 to 4) showed an insertional mutation at position 2480 of the *TRPS1* gene. The insertion resulted in a frameshift and predicted premature translational stop 3 codons after the insertion. The unaffected father and sister of patient 4 did not carry the mutated gene.

COMMENT

The TRPS I is characterized by the triad of hair alterations, craniofacial changes, and skeletal abnormalities, with high penetrance and variable expressivity. Craniofacial abnormalities include a bulbous pear-shaped nose, a long philtrum, a thin upper lip, and maxillary prognathism with mandibular hypoplasia.[1,7,8] Sometimes these distinctive facial changes are very subtle, and careful clinical examination may be necessary to identify affected individuals.

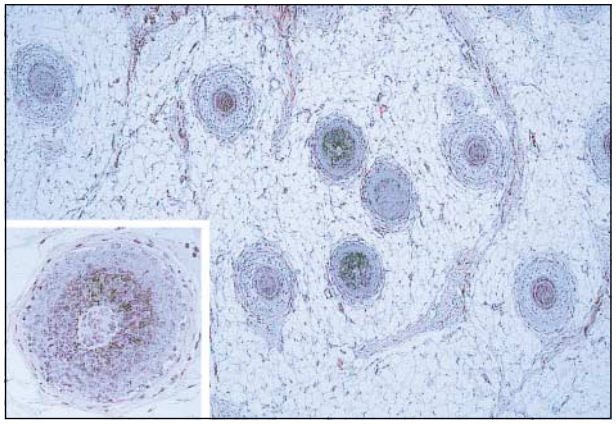

Figure 9. Transverse sections of scalp biopsy specimen (patient 1) showing hypoplasia of the dermal papillae (inset) (hematoxylin-eosin, original magnification ×50; inset original magnification ×200).

Trichologic abnormalities include fine, sparse, or even brittle scalp hair[9-12] and diffuse alopecia ranging from almost normal hair covering to severe hypotrichosis. In very rare cases, the scalp may be completely bald.[1,13] In many patients, scalp hairs grow significantly more slowly than in healthy individuals and, thus, reach only a limited length.[7,10,12,14,15] Two of our patients also complained about decelerated hair growth, although no impairment was noted in patients 3 and 4. The frontotemporal hairline is usually receded; the occipital hairline is only occasionally receded.[10,16] For the first time, we observed a receded medio-occipital hairline of roughly triangular shape in all of our familial cases. The lateral eyebrows are typically scanty[8,11,14-19] and, less often, the eyelashes may also be rarefied to virtually absent, as in our familial cases.[7,10,13-17] Sparseness of hairs may also affect the beard[16,17] and the axillary and pubic hair.[10]

Findings of previous hair and scalp examinations in TRPS I are limited and at times contradictory. An increased percentage of telogen and/or dysplastic hair roots in trichograms has been repeatedly described.[9,14,16,18,19] Structural alterations of the hair shaft were denied in several previous reports,[7,8,14,20] whereas others, in agreement with our findings, stressed a marked decrease of the diameter of scalp hair shafts.[9,16,18] Abnormalities of the cuticular pattern were noted in detailed scanning electron microscopic studies.[16,18] Rarely, configurational disturbances of the hair shafts in terms of cannulation or flattening have been found.[15,16,19] Quantitative measurements of viscoelastic hair variables showed a significant increase of the viscous measure, possibly because of increased disulfide bridging.[21] Lalević-Vasić et al[16] observed an unusual type of distal hair fracture that they called "finger-end rhexis" in addition to unspecific trichorrhexis nodosa and trichoptilosis. The most conspicuous light microscopic finding in our patients was a continuous thinning of the distal part of the hair shafts in the vast majority of the numerous hairs examined, which has never been described before, to our knowledge. The tapered tips can be easily explained by the markedly re-

©2001 American Medical Association. All rights reserved.
Downloaded From: http://archderm.jamanetwork.com/ on 05/19/2013

duced speed of the hair growth, making haircuts rarely necessary.[22]

Some of the few histologic descriptions restrict themselves to the notion of decreased[15,23] or small[10,16] hair follicles, since gross alterations are lacking. In the biopsy specimens of our patients, we could confirm the interesting previous observation of a relative hypoplasia of the dermal papillae inserting into well-developed hair matrixes.[9] Thus, the synthesis of thin hairs does not appear to be caused by a primary epithelial defect but, as van Neste and Dumortier[9] have assumed, by a disturbed dermoepidermal interrelation at the level of the hair root. Summing up the main trichologic findings in TRPS I, the impression of sparse scalp hair is mainly caused by a marked thinning of individual hairs and not by an important reduction of hair follicles.

Although some authors did not observe any nail changes in patients with TRPS I,[8,11,18] others describe thin and fragile nails,[7,14] sometimes with longitudinal striation,[16] which grow very slowly[7,12,14] or have never required a cut.[14] Additional nail changes in TRPS I include shortening and broadening of nails, giving rise to the appearance of racket nails.[12,15,17] "True" racket nails are transmitted in an autosomal dominant way and are associated with a wide and short distal phalanx.[23,24] Three of our patients had shortening of several distal phalanges and consecutive formation of racket nails. Further nail changes in TRPS I are leukonychia and koilonychia, the latter being observed in 7 of 9 affected members of a large family with TRPS I.[17]

Skeletal abnormalities imply that TRPS I is not merely a cosmetic problem. Important skeletal features include brachydactyly and brachytarsia, deviation of the proximal and (less frequently) of the distal phalanges, painless swelling of the proximal interphalangeal joints, and hip changes. Almost all patients with TRPS I also present with short stature of different expressivity.[1,17] Accordingly, the height of all of our 3 family members was below the third percentile.

On radiologic examination, cone-shaped epiphyses of the middle phalanges are the most frequent finding, but changes of the proximal or distal phalanges can also be present.[18,25,26] In a study by Giedion[25] evaluating radiographs of 69 patients with TRPS I, 52% of affected individuals had short metacarpals. Less frequently, shortening of metatarsals is observed. Recently, monozygotic twins were observed with only 1 sibling being affected by avascular necrosis of the femoral head.[27]

Several reports describe an association of TRPS I with endocrine disturbances, such as idiopathic hypoglycemia,[28] diabetes mellitus,[29] and hypothyroidism.[14] Interestingly, 1 of our 2 affected sisters (case 2) had had insulin-dependent diabetes mellitus since age 15 years. Naselli et al[27] described monozygotic twins with deficient growth hormone and insulinlike growth hormone secretion. Administration of recombinant human growth hormone was ineffective in these cases. Considering the heterogeneity of the mentioned endocrine changes, a relationship to the underlying *TRPS1* mutations seems unlikely. Furthermore, hereditary stenosis of the ureter-bladder junction and vesicoureteral reflux[15] have been described in 1 case of TRPS I.

Recently, the gene responsible for TRPS I was cloned, allowing mutation analysis of affected individuals and their relatives. We identified a de novo deletional mutation in our sporadic case and an insertional mutation in all 3 affected members of a family (cases 2 to 4), leading to a premature termination codon in all cases. These mutations occurred in exon 5 of the *TRPS1* gene, presumably causing reduced protein concentration that cannot be compensated for by the unaffected allele. Recently, in a study by Lüdecke et al,[4] 51 patients with TRPS were screened for genotype-phenotype correlation concerning bone deformities. In addition to the 2 mutations described herein, a total of 33 mutations were identified throughout the *TRPS1* gene.

All 3 affected individuals in the family we studied carry the same mutation. Nevertheless, the variation in clinical signs of these patients is striking. While the mother and her older daughter had only discrete alopecia and hardly disturbed hair growth, the younger daughter presented with fine, slow-growing hair and diffuse alopecia. We assume that, because of the great variability of clinical features, many cases of TRPS I remain undiagnosed until a more severely affected family member shows the classic signs and consults a physician. The sparse hair is often the most disturbing sign for which the patients seek medical advice.[18]

Careful clinical and, in case of suspicion, radiologic examination should be performed to identify potential mutation carriers.

Accepted for publication July 23, 2001.

We thank the affected individuals for their kind cooperation, M. Stephan for embedding of hair shafts, and C. Rose, MD, for discussions concerning scalp histologic examination.

Corresponding author and reprints: Cornelia Sabine Seitz, MD, Department of Dermatology, University of Würzburg, Josef-Schneider-Str 2, 97080 Würzburg, Germany (e-mail: cornelia.seitz@mail.uni-wuerzburg.de).

REFERENCES

1. Giedion A. Das tricho-rhino-phalangeale Syndrom. *Helv Paediatr Acta.* 1966;5:475-482.
2. Giedion A, Burdea M, Fruchter Z, Meloni T, Trosc V. Autosomal dominant transmission of the tricho-rhino-phalangeal syndrome: report of 4 unrelated families, review of 60 cases. *Helv Paediatr Acta.* 1973;28:2249-2259.
3. Momeni P, Glöckner G, Schmidt O, et al. Mutations in a new gene, encoding a zinc-finger protein, cause tricho-rhino-phalangeal syndrome type I. *Nat Genet.* 2000;24:71-74.
4. Lüdecke HJ, Schaper J, Meinecke P, et al. Genotypic and phenotypic spectrum in tricho-rhino-phalangeal syndrome types I and III. *Am J Hum Genet.* 2001;68:81-91.
5. Niikawa N, Kamei T. The Sugio-Kajii syndrome, proposed tricho-rhino-phalangeal syndrome type III. *Am J Med Genet.* 1986;24:759-760.
6. Sperling LC, Lupton GP. Histopathology of non-scarring alopecia. *J Cutan Pathol.* 1995;22:97-114.
7. Rodriguez-Serna M, Serrano G, Perez A, Aliaga A. What syndrome is it? Tricho-rhinophalangeal syndrome. *Pediatr Dermatol.* 1993;10:385-387.
8. George S, Pulimood S, Korah I. Trichorhinophalangeal syndrome type I. *J Eur Acad Dermatol Venereol.* 1998;11:66-68.
9. van Neste D, Dumortier M. Tricho-rhino-phalangeal syndrome: disturbed geometric relationships between hair matrix and dermal papilla in scalp hair bulbs. *Dermatologica.* 1982;165:16-23.
10. Camacho F, Armijo M, Naranjo R, Dulanto F. Le syndrome Tricho-Rhino-Phalangien (Giedion). *Ann Dermatol Venereol.* 1978;105:17-21.

©2001 American Medical Association. All rights reserved.
Downloaded From: http://archderm.jamanetwork.com/ on 05/19/2013

11. Marchand C, Villedieu MH, Plauchu H, Rigot-Muller G, Chouvet B. Syndrome trichorhinophalangien: a propos d'une observation. *Ann Dermatol Venereol*. 1985; 112:973-980.
12. Carrington PR, Chen H, Altick JA. Trichorhinophalangeal syndrome, type I. *J Am Acad Dermatol*. 1994;31:331-336.
13. Besser F, Wells RS. The tricho-rhino-phalangeal syndrome (a family with three affected members). *Br J Dermatol*. 1976;95(suppl 14):39-41.
14. Voigtländer V, Osswald F. The tricho-rhino-phalangeal syndrome. *Dermatologica*. 1978;156:34-39.
15. Yanez S, Hernandez-Vicente I, Armijo M. Trichorhinophalangeal syndrome. *Int J Dermatol*. 1992;31:706-709.
16. Lalević-Vasić BM, Nikolic MM, Polic DJ. Étude des cheveux: du syndrome trichorhinophalangien type I. *Ann Dermatol Venereol*. 1994;121:618-622.
17. Peltola J, Kuokkanen K. Tricho-rhino-phalangeal syndrome in five successive generations. *Acta Derm Venereol*. 1978;58:65-68.
18. Prens EP, Peereboom-Wynia JDR, De Bruyn WC, Van Joost T, Stolz E. Clinical and scanning electron microscopic findings in a solitary case of trichorhinophalangeal syndrome type I. *Acta Derm Venereol*. 1984;64:249-253.
19. Böni R, Huch Böni R, Tsambaos D, Spycher MA, Trüeb RM. Trichorhinophalangeal syndrome. *Dermatology*. 1995;190:152-155.
20. McCloud DJ, Solomon LM. The tricho-rhino-phalangeal syndrome. *Br J Dermatol*. 1977;96:403-407.
21. Schacht V, Borelli S, Tsambaos D, Spycher MA, Trüeb RM. Das Trichorhinophalangealsyndrom. *Hautarzt*. 2001;52:51-55.
22. Pashayan H, Solomon LM, Chan G. The tricho-rhino-phalangeal syndrome. *AJDC*. 1974;127:257-261.
23. Baden HP. Development and hereditary disorders of the nails. In: *Diseases of the Hair and Nails*. Chicago, Ill: Year Book Medical Publishers; 1987:70-97.
24. Baran R, Juhlin L. Bone dependent nail formation. *Br J Dermatol*. 1986;114:371-375.
25. Giedion A. Phalangeal cone-shaped epiphyses of the hand: their natural history, diagnostic sensitivity, and specificity in cartilage hair hypoplasia and the tricho-rhinophalangeal syndromes I and II. *Pediatr Radiol*. 1998;28:751-758.
26. Hornsby V, Pratt A. The tricho-rhino-phalangeal syndrome. *Clin Radiol*. 1984; 35:243-247.
27. Naselli A, Vignolo M, Di Battista E, et al. Trichorhinophalangeal syndrome type I in monozygotic twins discordant for hip pathology: report on the morphological evolution of cone-shaped epiphyses and the unusual pattern of skeletal maturation. *Pediatr Radiol*. 1998;28:851-855.
28. Parkhurst RD, Light GS, Bacon GE, Gall JC Jr. Tricho-rhino-phalangeal syndrome with hypoglycemia: case report with endocrine function studies. *South Med J*. 1972;65:457-459.
29. Walravens PA, Hambridge KM, Wesenberg RI, Greensher A. Endocrine and radiological abnormalities associated with the tricho-rhino-phalangeal (TRP) syndrome [abstract]. *Clin Res*. 1975;23:147A.

ARCHIVES Features

1. **Free color** publication if color illustrations enhance the didactic value of the article.
2. **Rapid publication.** The time from acceptance to publication in our March 2001 issue was 3.2 months.
3. **Expedited review** on request from authors.
4. **Archives Express.** Manuscripts with high priority can be reviewed, accepted, and published within 6 to 8 weeks.
5. **Research Trainee Award of $1000** for the resident or fellow who is the first author of the best research paper of the past year.
6. **Dermatologic Surgery Trainee Award of $1000** for the resident or fellow who is the first author of the best article on surgical dermatology published in the past year.
7. **Free distribution of the journal** to all residents and clinical dermatologists in the United States.

©2001 American Medical Association. All rights reserved.
Downloaded From: http://archderm.jamanetwork.com/ on 05/19/2013