OBSERVATION

Endothelial Damage in All Types of T-Lymphocyte–Mediated Drug-Induced Eruptions

Laurence Verneuil, MD, PhD; Christophe Leboeuf, PhD; Jean-Sébastien Vidal, MD, PhD; Philippe Ratajczak, PhD; François Comoz, MD; Jean-Claude Ameisen, MD, PhD; Anne Janin, MD, PhD

Background: In severe drug-induced eruptions, bullous lesions can be associated with immune complex–mediated vasculitis and/or with T-lymphocyte–mediated keratinocyte apoptosis. We have recently identified endothelial cell apoptosis in severe bullous T-lymphocyte–mediated drug-induced eruptions. We assessed microvessel involvement in the whole spectrum of T-lymphocyte–mediated drug-induced eruptions. Thirty-two patients with T-lymphocyte–mediated drug-induced eruptions in 4 groups (8 cases of toxic epidermal necrolysis/Stevens-Johnson syndrome, 8 cases of drug rash with eosinophilia and systemic symptoms, 8 cases of acute generalized exanthematous pustulosis, 8 cases of drug maculopapular exanthema) and 8 healthy controls were included. On skin biopsy specimens, we performed a systematic ultrastructural study of endothelial cells, vascular walls, and inflammatory cells; a quantification of apoptotic cells, inflammatory infiltrate, and immune complex deposits; and we assessed granzyme-B, tumor necrosis factor, and Fas ligand expression. Correlations of apoptosis with clinical data of skin lesions and systemic involvement in liver, kidney, lung, and lymph nodes were then assessed.

Observations: Findings from ultrastructural study showed that endothelial cell apoptosis was present in all 32 drug-induced eruptions. No leukocytoclastic vasculitis was associated. Granzyme-B and tumor necrosis factor were expressed around microvessels. In toxic epidermal necrolysis/Stevens-Johnson syndrome and drug rash with eosinophilia and systemic symptoms, the number of apoptotic endothelial cells was related to the extension of skin lesions and the presence of purpura. It was also related to liver and kidney involvement.

Conclusions: Endothelial apoptosis occurs in skin microvessels of all types of T-lymphocyte–mediated drug-induced eruptions. This skin endothelial cell damage is related to the severity of skin lesions and systemic involvement.

Arch Dermatol. 2011;147(5):579-584

Author Affiliations: Departments of Dermatology (Dr Verneuil) and Pathology (Dr Comoz), Centre Hospitalier Universitaire (CHU) Caen, Caen, France; Université Paris 7, Paris, France (Drs Leboeuf, Ratajczak, Ameisen, and Janin); Inserm U728, Paris (Drs Verneuil, Leboeuf, Ratajczak, Ameisen, and Janin); Inserm U708, Paris (Dr Vidal); and Department of Pathology, Saint-Louis Hôpital, Assistance Publique–Hôpitaux de Paris, Paris (Dr Janin).

DRUG-INDUCED ERUPTIONS are linked to immune reactions.[1] Drug-induced leukocytoclastic vasculitis mediated by immune complexes has been characterized since 1952,[2] but drug-induced delayed hypersensitivity reactions, mediated by T cells, have only been recently subdivided.[3] They include toxic epidermal necrolysis (TEN)/Stevens-Johnson syndrome (SJS) a severe bullous drug-induced eruption; drug rash with eosinophilia and systemic symptoms (DRESS); acute generalized exanthematous pustulosis (AGEP); and drug maculopapular exanthema (DMPE). We have recently identified endothelial cell apoptosis in skin microvessels of TEN/SJS,[4] the most severe form of T-lymphocyte–mediated drug-induced eruptions. To our knowledge, no systematic assessment of microvessel involvement has been performed in the other types of T-lymphocyte–mediated drug-induced eruptions. In another type of T-lymphocyte–mediated disease, acute graft-vs-host disease (GVHD), we identified endothelial cell apoptosis in human digestive tract biopsy specimens.[5,6] In an experimental model of allogeneic reactions, we demonstrated that these lesions, mediated through the Fas-Fas ligand (FasL) pathway, were present in skin, digestive tract, and liver, the classic target organs of acute GVHD, but also extended to the lungs and kidney.[7,8]

Herein, we systematically studied microvessel involvement in skin biopsy specimens of the different types of T-lymphocyte–mediated drug-induced eruptions and further assessed the relations with systemic involvement.

©2011 American Medical Association. All rights reserved.
Downloaded From: http://archderm.jamanetwork.com/ on 05/22/2013

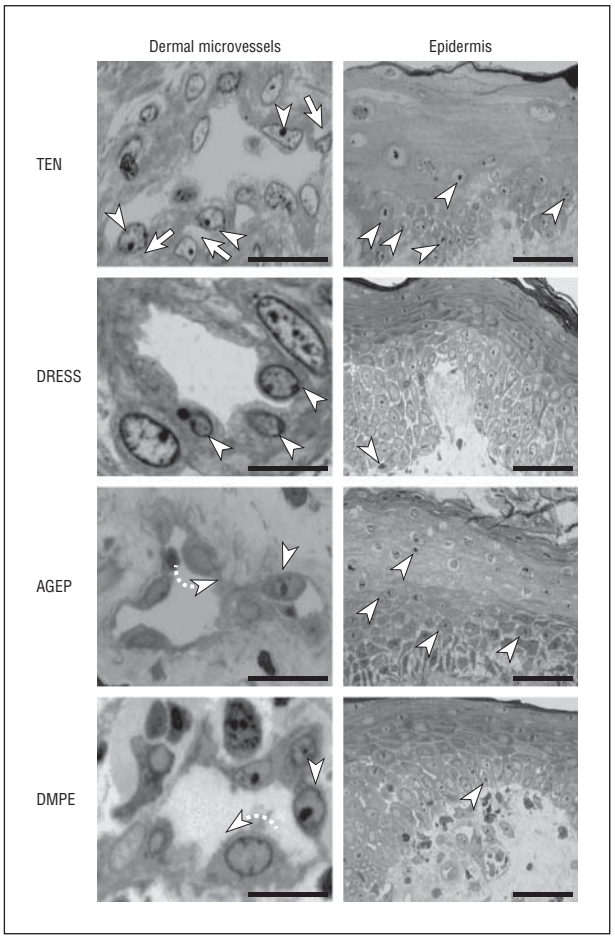

Figure 1. Endothelial cell and keratinocyte apoptosis in the 4 T-lymphocyte–mediated drug-induced eruptions. In drug maculopapular exanthema (DMPE), ultrastructure showed turgescent endothelial cells with cytoplasmic villi (curved arrow), together with isolated apoptotic endothelial cell (arrowhead). In the epidermis, few apoptotic keratinocytes (arrowhead) are also found in the basal layer. In acute generalized exanthematous pustulosis (AGEP), apoptotic endothelial cells (arrowheads) and endothelial cells with features of activation (curved arrow) were also found in the same microvessel section. Apoptotic keratinocytes were more numerous than in DMPE and localized in the different epidermal layers. Compared with DMPE and AGEP, toxic epidermal necrolysis (TEN) and drug rash with eosinophilia and systemic symptoms (DRESS) had a higher number of apoptotic endothelial cells (arrowheads). Subendothelial clefts (arrows) could be observed in TEN microvessel, together with a high number of apoptotic keratinocytes (arrowheads) in the epidermal layer. Bars = 25 μm.

METHODS

Over a period of 5 years (2003-2008), 103 patients from Caen University Hospital, Caen, France, had T-lymphocyte–mediated drug-induced eruptions, according to clinical and pathological criteria and drug imputability.[9] Among them, 32 patients were retrospectively included in this study because they had available snap-frozen and glutaraldehyde-fixed skin samples. There were 8 cases of DMPE (4 female and 4 male; median age, 57.5 [range, 34-86] years), 8 cases of DRESS (5 female and 3 male; median age, 40 [range, 18-90] years), 8 cases of AGEP (5 female and 3 male; median age, 75.5 [range, 44-93] years), and 8 cases if TEN/SJS (4 female and 4 male; median age, 48 [range, 38-87] years) previously reported.[4] The following clinical data were noted: (1) skin lesion extent greater than 60%, (2) presence of blisters and/or erosions, (3) presence of mucous lesions, (4) presence of purpura, and (5) liver, kidney, lung, and lymph node involvement. Liver involvement was defined by an increase in transaminase level; kidney involvement by increases in serum creatinine and blood urea nitrogen over normal laboratory values; lung involvement by a dyspnea associated with a noncardiogenic pulmonary edema or an interstitial pneumonia; and lymph node involvement by a lymphadenopathy, defined as palpable lymph node. The study was performed on the remaining skin samples left after diagnosis was established and on skin biopsy specimens for the 8 healthy controls (5 female and 3 male; median age, 50 [range, 30-61] years), previously studied.[4] The Caen University Research Ethics Committee approved the study protocol, and all patients and healthy controls gave their informed consent.

Skin biopsies performed for diagnostic purpose 2 to 4 days after eruption onset and before any steroid therapy, were divided into 3 parts. One was formaldehyde fixed and paraffin embedded, 1 was snap frozen, and 1 was glutaraldehyde fixed for electron microscopy. Ultrastructural study focused on microvessels, particularly endothelial cells and basal membrane, inflammatory infiltrate, and keratinocytes. Apoptotic cells were counted on TUNEL (terminal deoxynucleotidyl transferase-mediated biotin–deoxyuridine triphosphate nick-end labeling).[10] Immunostainings, performed on following sister tissue sections, allowed inflammatory cell and cytotoxic effector molecule analyses, with antihuman monoclonal antibodies CD4 (1F6; Novocastra Laboratories Ltd, Newcastle upon Tyne, England), CD8 (4B11; Novocastra), CD15 (P12; Abcam, Cambridge, Massachusetts), CD20 (L26; Abcam), CD68 (KP1; Dako Corp, Glostrup, Denmark), granzyme-B (GrB-7; Dako Corp), FasL (G247-4; BD-Pharmingen, San Diego, California), tumor necrosis factor (TNF) (52B83; Abcam), and controls with irreleveant isotypic antibodies and lack of primary antibody. Immune-complex deposits were detected with fluorescent polyclonal antihuman IgG, IgA, IgM, and C3 antibodies (Dako Corp).

Counts were performed on 3 different fields for each section by 2 pathologists blind to the diagnosis (F.C. and A.J.) on Olympus-AX-70 microscope (Olympus Corporation, Tokyo, Japan) with wide-field eyepiece number 26.5 providing 0.344 mm^2 field-sizes at ×400 magnification. Results were expressed as mean (SD) number of cells per 3 fields at ×400 magnification. The 2 pathologists used separate slides randomly to count different cells. For the apoptotic cell counts, group comparisons were done with the Mann-Whitney test. $P < .05$ was considered significant.

RESULTS

Endothelial cell apoptosis was identified in all 4 types of T-lymphocyte–mediated drug-induced eruptions (**Figure 1** and **Figure 2**). Ultrastructural study findings showed apoptotic endothelial cells without vascular wall damage in superficial dermal capillaries and postcapillary venules in all 32 drug-induced eruptions. Very few apoptotic endothelial cells were found in healthy control skin biopsy specimens. Endothelial cell apoptosis was focal, and different lesional stages were observed concomitantly on the same biopsy specimens: (1) signs of endothelial cell activation with prominent intraluminal nucleus, cytoplasmic microvilli, and vacuoles, (2) presence of apoptotic nuclei, (3) subendothelial cleft, and (4) loss of endothelial cells.

Apoptotic endothelial cell counts were significantly higher in the 32 drug-induced eruptions than in healthy controls. They were also significantly higher in TEN/SJS and DRESS than in DMPE and AGEP. No significant difference between TEN/SJS and DRESS or between DMPE and AGEP was observed.

©2011 American Medical Association. All rights reserved.
Downloaded From: http://archderm.jamanetwork.com/ on 05/22/2013

Apoptotic keratinocytes were found at different epidermal levels—the basal layer in TEN/SJS, the granular layer in AGEP, and were scattered over the epidermis in DRESS and DMPE. Apoptotic keratinocyte counts were significantly higher in TEN/SJS than in healthy controls but not in DRESS compared with healthy controls. Interestingly a significant difference with healthy controls was also observed in apoptotic cell counts for AGEP but not for DMPE.

MICROVESSEL DAMAGE WAS LIMITED TO ENDOTHELIAL CELL APOPTOSIS

In all 32 drug-induced eruptions, infiltrate density was higher than in healthy controls ($P<.001$). Neutrophil (8.7%; range, 8%-10%) and eosinophil (7.5%; range, 4%-12%) percentages were low. No leukocytoclasia, vascular wall necrosis, perivascular hemorrhage, or thrombosis was found in any of the 32 drug-induced eruptions studied (**Table 1**). Pericapillary IgG and complement deposits were found in 1 TEN/SJS case (eFigure; http://www.archdermatol.com), 2 DRESS cases, and 1 AGEP case. T lymphocytes (53.2%; range, 49%-56%) were more numerous than macrophages (27.3%; range, 20%-36%), with few B lymphocytes. CD4/CD8 ratio was less than 1 when the 32 cases were globally considered but varied with the type of T-lymphocyte–mediated drug-induced eruption; less than 1 in severe forms (TEN/SJS and DRESS); and greater than 1 in AGEP and DMPE. In the case of cytotoxic effector molecules, granzyme-B and TNF were more expressed in TEN/SJS and DRESS than in AGEP and DMPE; FasL was not expressed in any of the cases studied (Table 1).

ENDOTHELIAL CELL APOPTOSIS WAS RELATED TO CLINICAL SEVERITY

Considering the 16 TEN/SJS and DRESS cases, apoptotic endothelial cell numbers were significantly related to (1) skin lesion extent greater than 60%, (2) presence of purpura, and (3) liver and kidney involvement. In the same skin samples, the number of apoptotic keratinocytes was significantly related to the presence of blisters and/or erosions and to mucous lesions but not to skin lesion extent greater than 60%, presence of purpura, or systemic involvement (**Table 2**). Considering the 16 DMPE and AGEP cases, endothelial cell apoptosis was significantly related to the presence of purpura but not to any systemic involvement. In the same skin samples, there was no correlation between keratinocyte apoptosis and clinical data (Table 2).

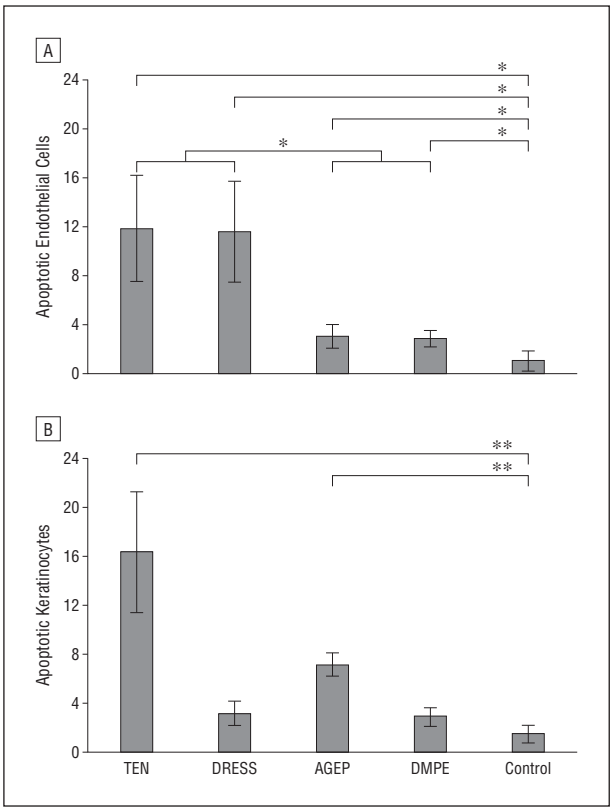

Figure 2. Mean number per field of apoptotic endothelial cells (A) and apoptotic keratinocytes (B). AGEP indicates acute generalized exanthematous pustulosis; DMPE, drug maculopapular exanthema; DRESS, drug rash with eosinophilia and systemic symptoms; and TEN, toxic epidermal necrolysis; $*P<.05$. $**P<.01$.

COMMENT

We identified endothelial cell apoptosis in skin microvessels of 4 different types of T-lymphocyte–mediated drug-induced eruptions with different degrees of clinical severity. These skin lesions, linked to delayed drug hypersensitivity reactions, have been recently subclassified into T-cell reactions that preferentially activate and recruit monocytes (type IVa), eosinophils (IVb), and neutrophils (IVd) through the release of cytokines and chemokines. Cytotoxic functions by CD4 or CD8 T-cells (type IVc) seem to participate in all type IV reactions.[3] CD8 T lymphocytes and apoptotic endothelial cells were found in our 32 cases, but even when endothelial detachment was observed, there was no association with vascular wall damage such as vessel wall fibrinoid necrosis, perivascular hemorrhage, or thrombosis. These features, together with the absence of leucocytoclasia, are different from leukocytoclastic vasculitis.[11] Moreover, immune-complex deposits were only detected in 4 of 32 cases. In vitro, immune complexes are able to activate neutrophils, which release lysosomal enzyme,[12] and lysosomal proteinases with oxygen metabolites that alter subendothelial basement membrane.[13] Features of eosinophil-linked cutaneous vasculitis were also not found in our cases. In this type of microvessel vasculitis, the mechanisms leading to endothelial cell damage are linked to cytotoxic properties of activated eosinophils[14] and to thrombotic effects of eosinophil major basic protein[15] and eosinophil peroxidase.[16]

In T-lymphocyte–mediated drug-induced eruptions, the mechanisms leading to endothelial cell damage could be linked to T cells, but also to macrophage activation, 2 prominent perivascular cell types. Granzyme-B, a cytotoxic protein able to experimentally induce endothelial cell apoptosis,[17] was expressed around microvessels in the 32 cases; however, we did not observe direct cytoplasmic contacts between lymphocytes and apoptotic endothelial cells.

©2011 American Medical Association. All rights reserved.
Downloaded From: http://archderm.jamanetwork.com/ on 05/22/2013

Table 1. Clinical and Microscopic Data in T-Lymphocyte–Mediated Drug-Induced Eruptions

Clinical Data	TEN/SJS (n=8)	DRESS (n=8)	AGEP (n=8)	DMPE (n=8)	Controls (n=8)
Skin lesions					
Extent area >60%	4	5	5	4	0
Blisters and/or erosions	8	1	6	1	0
Mucous lesions	7	0	2	0	0
Purpura	6	5	2	2	0
Systemic involvement					
Liver	5	5	2	2	0
Kidney	6	4	1	0	0
Lung	4	4	0	0	0
Lymph node	3	6	1	1	0
Cellular data in skin biopsy specimens					
Apoptotic endothelial cells[a]	11.8 (4.2)	11.5 (4.2)	3.1 (0.8)	2.8 (0.7)	1.0 (0.7)
Apoptotic keratinocytes[a]	16.4 (4.8)	3.4 (0.9)	7.0 (1.1)	3.0 (0.7)	1.5 (0.5)
Inflammatory infiltrate density[a]	172.3 (26.6)	238.2 (22.4)	130.1 (16.9)	123.6 (8.0)	18.1 (1.0)
Neutrophil %	9	8	8	10	5
Eosinophil %	4	6	8	12	0
Macrophage %	36	28	25	20	44
CD4 T cell %	20	20	32	26	33
CD8 T cell %	35	36	21	23	17
CD4/CD8 ratio	0.57	0.55	1.52	1.13	1.90
Cytotoxic effector molecule expression[a]					
Granzyme	44.1 (10.0)	41 (18.7)	16.5 (9.3)	10.1 (2.7)	0.0
TNF	38.2 (13.2)	34.3 (19.4)	13.2 (5.2)	12.4 (6.1)	2.0
FasL	1	2	1	1	0

Abbreviations: AGEP, acute generalized exanthematous pustulosis; DMPE, drug maculopapular exanthema; DRESS, drug rash with eosinophilia and systemic symptoms; FasL, Fas ligand; TEN/SJS, toxic epidermal necrolysis/Stevens-Johnson syndrome; TNF, tumor necrosis factor.
[a]Mean (SD) number of cells per 3 fields.

TNF and FasL are also able to induce in vitro endothelial cell apoptosis.[18,19] In vivo, we have previously shown that FasL is able to induce endothelial cell apoptosis in an experimental model of acute allogeneic reaction following T lymphocytes transfer in severe combined immunodeficient mice.[7] In our 32 T-lymphocyte–mediated drug-induced eruptions, TNF, but not FasL, was highly expressed, particularly in TEN/SJS and DRESS. This discrepancy could be related to the time of the biopsies, since a significant decrease in serum soluble FasL has been reported in TEN/SJS after only 3 days.[20]

Systematic ultrastructure allowed us to demonstrate that endothelial cell apoptosis was present in all types of T-lymphocyte–mediated drug-induced eruptions, but also that the microvessel damage was limited to endothelial cell without associated vascular wall damage. This latter feature had not been previously identified, perhaps because it cannot be easily detected on paraffin or frozen tissue sections. This endothelial damage could also be difficult to detect because of rapid endothelial repair. It has been established that apoptotic endothelial cells from the monolayer vascular endothelium can be cleared by the blood flow,[21,22] and that cell death through apoptosis does not induce inflammatory reaction.[23] Moreover, endothelial repair can rapidly occur through local migration and proliferation of adjacent endothelial cells to the site of injury[21,22] or through homing and incorporation of endothelial progenitor cells on the site of injury. Therefore, endothelial cell repair could more rapidly and efficiently occur when the lesion is limited to endothelial apoptosis without whole vascular wall damage.

As expected, the numbers of apoptotic keratinocytes was related to the presence of blisters and or erosions and of mucous lesions.[24] However, only the number of apoptotic endothelial cells was related to the extent of skin lesions. This involvement of microvessel damage in the severity of skin lesions in TEN/SJS and DRESS had, so far, not been reported. The number of apoptotic endothelial cells was related to the presence of purpura in all types of T-lymphocyte–mediated drug-induced eruptions studied. This underlines that even focal damage in the endothelial cover of the microvessel network favors red blood cell extravasation. Experimental studies of the endothelial barrier function using endotoxin-induced endothelial cell apoptosis demonstrated that disruption of endothelial monolayer was mediated in part through caspase cleavage of adherens junction proteins.[25] Moreover, FasL and perforin, cytotoxic effector molecules expressed by T lymphocytes, were able to induce endothelial cell apoptosis and vascular leak syndrome, without whole vascular wall disruption, as shown by ultrastructural study of lungs in mice.[26]

Also significant were the relations between the skin apoptotic endothelial cell numbers and liver and kidney involvement in TEN/SJS and DRESS cases. Extracutaneous organ damage have been reported in TEN/SJS and DRESS,[27] with development of systemic lesions in the liver,[28,29] digestive tract,[30] kidney,[31] and lung,[32] but no assessment of the microvessel involvement was performed in these cases.

The significant correlation between skin endothelial cell apoptosis and systemic involvement that we ob-

©2011 American Medical Association. All rights reserved.
Downloaded From: http://archderm.jamanetwork.com/ on 05/22/2013

Table 2. Clinical Data Relations With Endothelial Cell and Keratinocyte Apoptosis

Clinical Data	TEN/SJS and DRESS (n=16) No. (%)	Endothelial Apoptosis[a]	P Value[b]	Keratinocyte Apoptosis[a]	P Value[b]	AGEP and DMPE (n=16) No. (%)	Endothelial Apoptosis[a]	P Value[b]	Keratinocyte Apoptosis[a]	P Value[b]
Skin Lesions										
Extent area >60%										
Yes	9 (56.3)	15.1 (0.9)	.04	10.0 (8.1)	.15	9 (56.3)	2.78 (0.83)	.42	5.2 (2.16)	.20
No	7 (47.7)	5.1 (4.5)		9.7 (7.3)		7 (43.7)	3.14 (0.69)		4.7 (2.49)	
Blisters and/or erosions										
Yes	9 (56.3)	9.8 (6.1)	.61	15.1 (5.9)	.04	7 (43.7)	3.14 (0.89)	.32	6.1 (1.95)	.08
No	7 (43.7)	12.0 (5.8)		3.1 (0.7)		9 (56.3)	2.78 (0.66)		4.1 (2.14)	
Mucous lesions										
Yes	8 (50.0)	10.6 (5.9)	.61	16.4 (4.8)	.04	2 (12.5)	3.00 (0.00)	.48	4.8 (2.32)	.80
No	8 (50.0)	10.9 (6.3)		3.4 (0.9)		14 (87.5)	2.93 (0.82)		6.5 (0.70)	
Purpura										
Yes	11 (68.8)	14.3 (2.9)	.01	11.4 (7.9)	.18	4 (25.0)	2.25 (0.50)	.02	5.3 (2.62)	.40
No	5 (31.2)	3.0 (0.7)		6.6 (5.9)		12 (75.0)	3.17 (0.70)		4.9 (2.23)	
Systemic Involvement										
Liver										
Yes	10 (62.5)	15.1 (0.9)	.01	11.0 (8.3)	.16	4 (25.0)	2.75 (0.50)	.27	5.0 (1.82)	.89
No	6 (37.5)	3.5 (1.4)		8.0 (6.3)		12 (75.0)	3.00 (0.85)		5.0 (2.44)	
Kidney										
Yes	11 (68.8)	14.3 (2.9)	.01	11.4 (7.9)	.18	15 (94.0)	2.93 (2.26)	>.99	4.9 (2.26)	.75
No	5 (31.2)	3.0 (0.7)		6.6 (5.9)		1 (6.0)	3.00 (0.00)		7.00 (0.00)	
Lung										
Yes	8 (50.0)	12.1 (8.1)	.50	9.3 (8.1)	.85	0	0.00 (0.00)	NR	0.00 (0.00)	NR
No	8 (50.0)	9.4 (5.9)		10.5 (7.3)		16 (100)	2.94 (0.77)		5.0 (2.25)	
Lymph node										
Yes	9 (56.3)	11.3 (6.3)	.30	7.1 (7.1)	.35	14 (87.5)	2.98 (0.89)	.30	5.0 (2.21)	.09
No	7 (43.7)	10.0 (5.7)		13.4 (6.9)		2 (12.5)	2.93 (0.73)		5.0 (2.11)	

Abbreviations: AGEP, acute generalized exanthematous pustulosis; DMPE, drug maculopapular exanthema; DRESS, drug rash with eosinophilia and systemic symptoms; NR, not reported; TEN/SJS, toxic epidermal necrolysis/Stevens-Johnson syndrome.
[a] Mean (SD) number of apoptotic cells per 3 fields.
[b] Correlations between clinical data and cell apoptosis.

served in severe T-lymphocyte–mediated drug-induced eruptions might reflect a systemic endothelial cell involvement. The diffusion of drugs and the recirculation of activated T lymphocytes in the whole microvessel network could both favor this systemic involvement. In acute GVHD, activated T lymphocytes are able to induce endothelial cell apoptosis in the skin, as well as other target organs of alloimmune reaction, such as the liver, digestive tract, and lung.[5-8] Other teams also reported endothelial cell damage, and further systemic vascular damage at the chronic stage of GVHD in the skin.[33,34]

Concerning drugs, 2 types of interactions with T lymphocytes have been characterized: metabolization or degradation into reactive species, followed by combination with cellular protein to become haptens[35] or direct stimulation of T cells via interactions of the T-cell receptor in a major histocompatibility complex–restricted manner.[35,36] These interactions between drugs and T lymphocytes could participate in a systemic endothelial cell involvement in severe T-lymphocyte–mediated drug-induced eruptions.

In conclusion, microvessel damage occurs in all T-lymphocyte–mediated drug-induced eruptions and could contribute to clinical severity, in particular in severe forms.

Accepted for Publication: January 13, 2011.
Correspondence: Laurence Verneuil, MD, PhD, Department of Dermatology, CHU Caen, Avenue Georges Clemenceau, F-14033 Caen, France (verneuil-l@chu-caen.fr).
Author Contributions: Drs Leboeuf and Vidal contributed equally to this work. All authors had full access to all of the data in the study and take responsibility for the integrity of the data and the accuracy of the data analysis. *Study concept and design:* Verneuil, Ameisen, and Janin. *Acquisition of data:* Verneuil, Leboeuf, Ratajczak, and Comoz. *Analysis and interpretation of data:* Verneuil and Vidal. *Drafting of the manuscript:* Verneuil, Leboeuf, Ratajczak, Comoz, and Janin. *Critical revision of the manuscript for important intellectual content:* Vidal and Ameisen. *Statistical analysis:* Vidal. *Obtained funding:* Verneuil. *Administrative, technical, and material support:* Leboeuf and Comoz.
Financial Disclosure: None reported.
Funding/Support: This study was supported in part by the Société Française de Dermatologie, CHU Caen, INCa, Région Ile de France.

©2011 American Medical Association. All rights reserved.
Downloaded From: http://archderm.jamanetwork.com/ on 05/22/2013

Online-Only Material: The eFigure is available at http://www.archdermatol.com.
Additional Contributions: S. Arien and S. Lefrançois of the Department of Pathology at Hôpital Saint-Louis, Paris, France, provided technical assistance with electron microscopy and the technicians of the Department of Pathology at CHU Caen, France, also provided technical assistance.

REFERENCES

1. Coombs PR, Gell PG. Classification of allergic reactions responsible for clinical hypersensitivity and disease . Gell RR, ed. *Clinical Aspects of Immunology*. Oxford, England: Oxford University Press; 1968:575-596.
2. Zeek PM. Periarteritis nodosa; a critical review. *Am J Clin Pathol*. 1952;22(8):777-790.
3. Pichler WJ. Delayed drug hypersensitivity reactions. *Ann Intern Med*. 2003;139(8):683-693.
4. Verneuil L, Ratajczak P, Allabert C, et al. Endothelial cell apoptosis in severe drug-induced bullous eruptions. *Br J Dermatol*. 2009;161(6):1371-1375.
5. Ertault-Daneshpouy M, Leboeuf C, Lemann M, et al. Pericapillary hemorrhage as criterion of severe human digestive graft-versus-host disease. *Blood*. 2004;103(12):4681-4684.
6. Socié G, Mary JY, Lemann M, et al. Prognostic value of apoptotic cells and infiltrating neutrophils in graft-versus-host disease of the gastrointestinal tract in humans: TNF and Fas expression. *Blood*. 2004;103(1):50-57.
7. Janin A, Deschaumes C, Daneshpouy M, et al. CD95 engagement induces disseminated endothelial cell apoptosis in vivo: immunopathologic implications. *Blood*. 2002;99(8):2940-2947.
8. Deschaumes C, Verneuil L, Ertault-Daneshpouy M, et al. CD95 ligand-dependant endothelial cell death initiates oral mucosa damage in a murine model of acute graft versus host disease. *Lab Invest*. 2007;87(5):417-429.
9. Demoly P, Kropf R, Bircher A, Pichler WJ. Drug hypersensitivity: questionnaire: EAACI interest group on drug hypersensitivity. *Allergy*. 1999;54(9):999-1003.
10. Gavrieli Y, Sherman Y, Ben-Sasson SA. Identification of programmed cell death in situ via specific labeling of nuclear DNA fragmentation. *J Cell Biol*. 1992;119(3):493-501.
11. Lotti T, Ghersetich I, Comacchi C, Jorizzo JL. Cutaneous small-vessel vasculitis. *J Am Acad Dermatol*. 1998;39(5 Pt 1):667-687.
12. Lucisano YM, Mantovani B. Lysosomal enzyme release from polymorphonuclear leukocytes induced by immune complexes of IgM and of IgG. *J Immunol*. 1984;132(4):2015-2020.
13. Weiss SJ, Regiani S. Neutrophils degrade subendothelial matrices in the presence of alpha-1-proteinase inhibitor. Cooperative use of lysosomal proteinases and oxygen metabolites. *J Clin Invest*. 1984;73(5):1297-1303.
14. Chen KR, Pittelkow MR, Su D, Gleich J, Newman W, Leiferman KM. Recurrent cutaneous necrotizing eosinophilic vasculitis. A novel eosinophil-mediated syndrome. *Arch Dermatol*. 1994;130(9):1159-1166.
15. Tai PC, Ackerman SJ, Spry CJ, Dunnette S, Olsen EG, Gleich GJ. Deposits of eosinophil granule proteins in cardiac tissues of patients with eosinophilic endomyocardial disease. *Lancet*. 1987;1(8534):643-647.
16. Rohrbach MS, Wheatley CL, Slifman NR, Gleich GJ. Activation of platelets by eosinophil granule proteins. *J Exp Med*. 1990;172(4):1271-1274.
17. Choy JC, Cruz RP, Kerjner A, et al. Granzyme B induces endothelial cell apoptosis and contributes to the development of transplant vascular disease. *Am J Transplant*. 2005;5(3):494-499.
18. Robaye B, Mosselmans R, Fiers W, Dumont JE, Galand P. Tumor necrosis factor induces apoptosis (programmed cell death) in normal endothelial cells in vitro. *Am J Pathol*. 1991;138(2):447-453.
19. Li JH, Kluger MS, Madge LA, Zheng L, Bothwell AL, Pober JS. Interferon-gamma augments CD95(APO-1/Fas) and pro-caspase-8 expression and sensitizes human vascular endothelial cells to CD95-mediated apoptosis. *Am J Pathol*. 2002;161(4):1485-1495.
20. Murata J, Abe R, Shimizu H. Increased soluble Fas ligand levels in patients with Stevens-Johnson syndrome and toxic epidermal necrolysis preceding skin detachment. *J Allergy Clin Immunol*. 2008;122(5):992-1000.
21. Woywodt A, Bahlmann FH, De Groot K, Haller H, Haubitz M. Circulating endothelial cells: life, death, detachment and repair of the endothelial cell layer. *Nephrol Dial Transplant*. 2002;17(10):1728-1730.
22. Woywodt A, Haubitz M, Buchholz S, Hertenstein B. Counting the cost: markers of endothelial damage in hematopoietic stem cell transplantation. *Bone Marrow Transplant*. 2004;34(12):1015-1023.
23. Granville DJ, Carthy CM, Hunt DW, McManus BM. Apoptosis: molecular aspects of cell death and disease. *Lab Invest*. 1998;78(8):893-913.
24. Paul C, Wolkenstein P, Adle H, et al. Apoptosis as a mechanism of keratinocyte death in toxic epidermal necrolysis. *Br J Dermatol*. 1996;134(4):710-714.
25. Bannerman DD, Sathyamoorthy M, Goldblum SE. Bacterial lipopolysaccharide disrupts endothelial monolayer integrity and survival signaling events through caspase cleavage of adherens junction proteins. *J Biol Chem*. 1998;273(52):35371-35380.
26. Rafi AQ, Zeytun A, Bradley MJ, et al. Evidence for the involvement of Fas ligand and perforin in the induction of vascular leak syndrome. *J Immunol*. 1998;161(6):3077-3086.
27. Roujeau JC, Stern RS. Severe adverse cutaneous reactions to drugs. *N Engl J Med*. 1994;331(19):1272-1285.
28. Masiá M, Gutiérrez F, Jimeno A, et al. Fulminant hepatitis and fatal toxic epidermal necrolysis (Lyell disease) coincident with clarithromycin administration in an alcoholic patient receiving disulfiram therapy. *Arch Intern Med*. 2002;162(4):474-476.
29. Mennicke M, Zawodniak A, Keller M, et al. Fulminant liver failure after vancomycin in a sulfasalazine-induced DRESS syndrome: fatal recurrence after liver transplantation. *Am J Transplant*. 2009;9(9):2197-2202.
30. Chosidow O, Delchier JC, Chaumette MT, et al. Intestinal involvement in drug-induced toxic epidermal necrolysis [letter]. *Lancet*. 1991;337(8746):928.
31. Hung CC, Liu WC, Kuo MC, Lee CH, Hwang SJ, Chen HC. Acute renal failure and its risk factors in Stevens-Johnson syndrome and toxic epidermal necrolysis. *Am J Nephrol*. 2009;29(6):633-638.
32. Lebargy F, Wolkenstein P, Gisselbrecht M, et al. Pulmonary complications in toxic epidermal necrolysis: a prospective clinical study. *Intensive Care Med*. 1997;23(12):1237-1244.
33. Biedermann BC, Sahner S, Gregor M, et al. Endothelial injury mediated by cytotoxic T lymphocytes and loss of microvessels in chronic graft versus host disease. *Lancet*. 2002;359(9323):2078-2083.
34. Tichelli A, Gratwohl A. Vascular endothelium as "novel" target of graft-versus-host disease. *Best Pract Res Clin Haematol*. 2008;21(2):139-148.
35. Roychowdhury S, Svensson CK. Mechanisms of drug-induced delayed-type hypersensitivity reactions in the skin. *AAPS J*. 2005;7(4):E834-E846.
36. Schnyder B, Mauri-Hellweg D, Zanni M, Bettens F, Pichler WJ. Direct, MHC-dependent presentation of the drug sulfamethoxazole to human alphabeta T cell clones. *J Clin Invest*. 1997;100(1):136-141.

©2011 American Medical Association. All rights reserved.
Downloaded From: http://archderm.jamanetwork.com/ on 05/22/2013