ONLINE FIRST

A Randomized Trial of the Off-label Use of Imiquimod, 5%, Cream With vs Without Tazarotene, 0.1%, Gel for the Treatment of Lentigo Maligna, Followed by Conservative Staged Excisions

Mark A. Hyde, MMS, PA-C; Michael L. Hadley, MD; Payam Tristani-Firouzi, MD; David Goldgar, PhD; Glen M. Bowen, MD

Objective: To determine if the complete response rates of lentigo maligna (LM) to imiquimod, 5%, cream can be improved by the addition of a topical retinoid.

Design: Prospective randomized study of patients treated with imiquimod alone vs imiquimod plus a topical retinoid, followed by conservative staged excisions.

Setting: Mohs surgical clinic in an academic institution.

Patients: Ninety patients with biopsy-confirmed LM.

Interventions: Ninety patients with 91 LMs were randomized into 2 groups. One group received imiquimod, 5%, cream 5 d/wk for 3 months, while the other group also received tazarotene, 0.1%, gel 2 d/wk for 3 months. Following topical therapy, all patients underwent staged excisions and frozen section analysis with Melan-A immunostaining to confirm negative margins.

Main Outcome Measure: The presence or absence of residual LM at the time of staged excision.

Results: Forty-six patients with 47 LMs were randomized to receive monotherapy: 42 of 47 LMs reached the intended treatment duration, with 27 complete responses (64%). Forty-four patients with 44 LMs were randomized to receive combined therapy: 37 of 44 LMs reached the intended treatment duration, with 29 complete responses (78%). This difference did not reach statistical significance ($P=.17$). There have been no recurrences to date, with a mean follow-up period of 42 months.

Conclusions: Among patients who received topical imiquimod with vs without tazarotene, 22% (8 of 37) of lesions vs 36% (15 of 42) of lesions showed residual LM on staged excisions. Pretreating LM with imiquimod, 5%, cream may decrease surgical defect sizes; however, total reliance on topical imiquimod as an alternative to surgery may put the patient at increased risk of a local recurrence.

Trial Registration: clinicaltrials.gov Identifier: NCT00707174

Arch Dermatol. 2012;148(5):592-596.
Published online March 19, 2012.
doi:10.1001/archdermatol.2012.270

Author Affiliations: Department of Dermatology (Mr Hyde and Drs Hadley, Tristani-Firouzi, Goldgar, and Bowen) and Melanoma and Cutaneous Oncology Program, Huntsman Cancer Institute (Mr Hyde and Drs Hadley and Bowen), The University of Utah, Salt Lake City.

LENTIGO MALIGNA (LM) AND its invasive counterpart LM melanoma present daunting clinical challenges because of the difficulty in reliably procuring clear peripheral surgical margins to prevent local recurrences.[1] The current standard of care for the treatment of LM and LM melanoma is to perform staged surgical excisions in an attempt to verify negative perimeter margins before surgical repair.[2] Staged excisions have reduced perimeter recurrences but have not eliminated them. Unfortunately, staged excisions result in significant morbidity due to the large sizes of the LM defects compared with those of other melanoma subtypes. In addition, LM tends to occur in cosmetically sensitive areas, such as the head and neck. In a previous study[3] at our institution, less than 50% of LM staged excisions demonstrated negative tumor margins after 1 stage using 5-mm margins. A second study[4] of LM staged excisions using 2-mm to 3-mm margins showed that 50% of tumors were still present after 2 stages. A third study[5] calculated a mean requirement of 7.1-mm margins to clear LM. Because most LM tumors are located on the face and scalp, they often encroach on tissue at the nose, eyelids, ears, and lips. The subclinical extension of LM, leading to large surgical defect sizes, renders the use of a nonsurgical approach desirable.

Several nonsurgical treatments have been applied to LM but with high recurrence rates. Such techniques include cryo-

©2012 American Medical Association. All rights reserved.
Downloaded From: http://archderm.jamanetwork.com/ on 06/19/2013

surgery, 5-fluorouracil, azelaic acid, laser, and radiation therapy.[6-9] More recently, imiquimod (a novel immune response modifier) has been approved by the Food and Drug Administration for the treatment of genital warts, actinic keratoses, and superficial basal cell carcinoma of the trunk.[6,10,11] In addition, several case reports and small series have demonstrated the potential efficacy of imiquimod in LM.[12-14] Previously published were results on the treatment of 40 patients with topical imiquimod, followed by total removal of the tumor with staged excisions using conservative 2-mm margins; the data showed that 30 of 40 patients had no residual signs of tumor histologically at the time of surgery, for a complete response rate of 75%.[15]

The clinical response to imiquimod is not uniform among patients. Some respond rapidly, with significant signs of inflammation, while others fail to have any notable reaction to the medication. We theorized that we may be able to induce a more potent inflammatory response in those 25% of patients who do not achieve a complete response with imiquimod alone by enhancing drug penetration through disruption of the stratum corneal barrier with the addition of a topical retinoid (tazarotene, 0.1%, gel). The objective of this study was to evaluate the efficacy of adding topical tazarotene to a topical imiquimod regimen in treating LM vs a control group treated with imiquimod alone. Results were verified by complete staged excisions using 2-mm margins following completion of the topical therapy.

METHODS

The internal review board at The University of Utah School of Medicine approved a prospective randomized trial designed to include 80 patients with biopsy-proved LM (Huntsman Cancer Institute). This sample size was determined using data from a previous study[15] of 40 patients as a reference. Patients were randomized equally to 1 of 2 groups. One group received imiquimod, 5%, cream 5 d/wk (Monday through Friday), with an intended treatment duration of 3 months. The other group also received tazarotene, 0.1%, gel 2 d/wk (Saturday and Sunday). Patients were randomized using a 1:1 random number table for 2 interventions generated by the clinical trials office at our institution. Informed consent, enrollment, and randomizations were completed by a representative from the clinical trials office at our institution. Because of the nature of the treatment arms, study participants, medical staff, and study staff were not blinded after the assignment was made. To increase the likelihood of a significant result, the study protocol was amended to include an additional 10 patients to compensate for those who had dropped out. All 90 patients were enrolled between June 30, 2005, and March 14, 2008.

To avoid the risk of treating invasive LM melanoma with topical imiquimod, all visible signs of LM were removed using a shave excision at the first visit. Patients were asked to return in 1 month, allowing the biopsy wound to heal before starting topical treatment. If a nidus of invasion was identified histologically, the patient was ineligible for the study and proceeded straight to surgery. To identify tumor sizes as accurately as possible, the tumor was viewed under a Wood lamp, and the tumor outline was inscribed on the skin with a marking pen and transferred to a transparent plastic template. An India ink tattoo was placed in the center of the biopsy scar to enable centering of the template correctly over the tumor at the completion of therapy (**Figure 1**). In both treatment arms, patients were instructed to treat an area extending 1 in (2.54 cm) beyond the outlined tumor margins. Patients were monitored monthly to assess the degree of inflammation present clinically and to screen for any clinical signs of tumor regrowth during topical therapy.

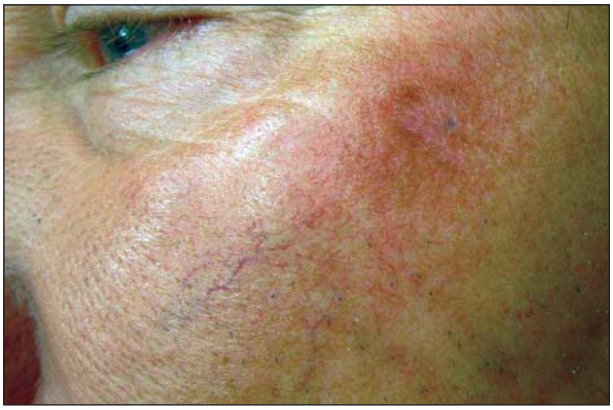

Figure 1. An India ink tattoo is placed in the center of the biopsy scar to enable centering of the template correctly over the tumor at the completion of topical therapy.

Figure 2. The tumor footprint is retraced onto the skin using the template with 2-mm margins added.

Inflammatory responses were graded by the maximum intensity observed using a scale of 0 to 3 (0 indicates no inflammation; 1, pink; 2, red; and 3, the presence of erosions, oozing, or eschar). Patients were instructed to stop treatment for 1 week if there was sufficient inflammation to cause oozing or crusting and then were allowed to restart treatment. Two months after cessation of topical treatment (to allow for resolution of inflammation), the tumor footprint was retraced onto the skin with the template (**Figure 2**) and excised using 2-mm margins via a staged excision with radial frozen sections[4] and Melan-A immunostaining.[16] Patients were considered to have a complete response if no residual LM was seen. Patients who had residual tumor centrally but had greater than 2 mm of uninvolved skin from the perimeter edge were considered to have an incomplete response but did not require additional stages of surgery. Patients who had residual tumor that extended to

©2012 American Medical Association. All rights reserved.
Downloaded From: http://archderm.jamanetwork.com/ on 06/19/2013

Table. Treatment Groups and Response to Treatment

Variable	Imiquimod-Alone Group (n = 46)[a]	Combined Imiquimod-Tazarotene Group (n = 44)[b]
Total lesions	47	44
Lesions reaching the intended treatment duration	42	37
Patient dropout		
Because of adverse effects	1	6
For other reasons	4	1
Lesions		
Complete response	27	29
Treatment failure	15	8

[a] Eleven female and 35 male.
[b] Thirteen female and 31 male.

within 2 mm of the outside edge of excision underwent additional stages of surgery. Once a negative margin was verified, surgical reconstruction was performed.

RESULTS

Ninety patients (24 women and 66 men) were enrolled; 47 LMs on 46 patients were randomized to receive imiquimod alone, while 44 LMs on 44 patients were randomized to receive both imiquimod and tazarotene (**Table**). The mean age of participants was 68.2 years (age range, 35-92 years). The ratio of men to women was 2.75:1. In the group treated with imiquimod alone, 41 of 46 patients (42 of 47 LMs) reached the intended treatment duration of 3 months, with 1 patient dropping out because of excessive inflammation and 4 patients dropping out for unrelated reasons. Of 42 LMs that were treated for 3 months, 27 had complete responses verified by staged excisions of the entire tumor footprint, for a complete response rate of 64% (27 of 42). In the group treated with combined imiquimod-tazarotene, 37 of 44 patients (37 of 44 LMs) reached the intended treatment duration, with 29 complete responses recorded at the time of surgery, for a complete response rate of 78% (29 of 37). The 14% difference in complete responses between the 2 groups did not meet statistical significance ($P=.17$).

Among 23 total lesions in both groups experiencing a treatment failure, all showed residual disease centrally. In 22 of 23 lesions, tumor extended to within 1 mm of the peripheral margin, requiring additional stages of surgery. A mean of 2.3 stages was required to obtain a clear perimeter margin. Generally, 3 to 4 mm was resected with each additional stage.

Six patients in the combined therapy group dropped out because of adverse effects, while 1 patient dropped out for reasons unrelated to treatment. Among the 6 with adverse effects, 5 went on to surgery; 4 of 5 documented complete responses, while 1 harbored residual disease, although these data were not included in the final analysis. One patient did not undergo surgery because of unrelated health issues.

In regard to clinically observed inflammation, 25 of 42 patients (60%) in the monotherapy group achieved a grade 2 or 3 inflammatory response, with 15 of 25 having no signs of tumor at the time of excision, for a 60% complete response rate. Seventeen of 42 patients (40%) achieved a grade 0 or 1 inflammatory response, with 12 of 17 having no residual tumor at excision, for a 71% complete response rate. In the combined therapy group, 30 of 37 patients (81%) achieved a grade 2 or 3 inflammatory response, with 26 of 30 (87%) having a complete response, while 7 of 37 patients (19%) had a grade 0 or 1 inflammatory response, with 3 of 7 having a complete response. Patients in the combined therapy group had a significantly higher overall inflammation score (mean, 2.3) than those in the monotherapy group (mean, 1.8) ($P=.02$). There have been no recurrences to date, with a mean follow-up period of 42 months.

Of 46 patients in the monotherapy group, 5 did not reach the intended treatment duration: 1 withdrew because of adverse effects in which the patient consistently developed a grade 3 inflammatory response despite successive 1-week drug holidays, for a 2% dropout rate because of adverse effects. The remaining 4 patients withdrew from the study for other reasons, such as withdrawal of informed consent or unrelated health issues. Of 44 patients in the combined therapy group, 7 did not reach the intended treatment duration: 6 withdrew because of adverse effects and 1 for unrelated reasons, for a 14% dropout rate because of adverse effects. Of note, despite the fact that we had removed all visible signs of tumor at the onset of topical therapy, 1 patient developed brown pigment at the treatment site in the 2-month interval between topical therapy completion and surgery. At surgery, this patient was found to have a nidus of invasive melanoma (0.32-mm Breslow depth and Clark level III). The patient subsequently underwent a full-thickness excision using 1-cm margins with intraoperative margin control and Melan-A immunostaining.

COMMENT

The data show a clear increase in clinical signs of inflammation when tazarotene was added to topical imiquimod, with 60% (25 of 42) of patients who received imiquimod alone achieving a grade 2 or 3 inflammatory response compared with 81% (30 of 37) of patients who received the imiquimod-tazarotene combination. The disparity in the rates of high-grade inflammation was 21% in favor of the combined therapy group, yet the overall 14% difference in complete responses between the 2 groups was more modest. Moreover, the data were paradoxical in the monotherapy group, where there was a 71% (12 of 17 patients) complete response rate among patients with modest degrees of inflammation vs a 63% (15 of 24 patients) complete response rate among patients with high degrees of inflammation. In the combined therapy group, 43% (3 of 7) of patients with lower degrees of inflammation had complete responses, while 87% (26 of 30) of patients with high degrees of inflammation had complete responses.

There are several possible explanations for the observed data. First, the study may have been underpowered, and had there been more patients, a statistical

©2012 American Medical Association. All rights reserved.
Downloaded From: http://archderm.jamanetwork.com/ on 06/19/2013

advantage might have been observed in those patients receiving both imiquimod and a topical retinoid. Second, the degree of the inflammatory response may not be as important as the quality of the inflammatory response. Compared with the nonresponders, the complete responders may produce a more effective inflammatory repertoire that does not directly correlate with the intensity of the inflammatory response seen on physical examination. Third, it may be that some LM cells are impervious to the inflammatory response regardless of its intensity or quality. Fourth, some patients may have a low density of toll-like receptors on the effector cells or may have a normal density of receptors but weak binding avidity to imiquimod that is not directly reflected in the clinically observed inflammatory response.

As physicians, we are left to sort out the relative value of pretreating patients having LM using imiquimod with vs without a topical retinoid, followed by conservative staged excisions. Based on prior published experience of finding invasive melanoma at the time of staged excisions in patients referred with a diagnosis of LM (16% had unanticipated invasion seen on staged excisions),[3] it is our standard of practice to remove all the observable tumor before commencing topical therapy. In addition, while patients are receiving topical therapy, we evaluate each patient monthly to ensure that he or she is not developing any clinical signs to suggest that the melanoma is recurring. Indeed, 1 patient in this study developed clinical signs of tumor regrowth between the cessation of topical therapy and the staged excision and had a thinly invasive melanoma, a diagnosis that was initially excluded by complete saucerization of the tumor before commencing topical therapy. This case demonstrated that the development of an invasive melanoma can occur following saucerization (presumably due to repopulation from follicular or perimeter involvement), and a high degree of clinical surveillance is warranted in all patients.

Herein, our absolute best complete response rate with topical treatment was 78% (29 of 37 LMs in the combined therapy group), theoretically optimized by the addition of a topical retinoid; therefore, using topical imiquimod as an alternative to surgery carries a potentially increased risk of a local recurrence. What then is the usefulness of using topical imiquimod in LM? It is our opinion that topical imiquimod is useful as a means of reducing the morbidity of LM surgery and possibly decreasing recurrence rates. When LM occurs at cosmetically sensitive sites where surgical defect sizes are more likely to be morbid, it is our current practice to surgically remove all visible evidence of LM at the initial consultation to rule out unexpected invasion by saucerizing the entire tumor as viewed under a Wood lamp. We create a template of the tumor footprint, as previously discussed. The patient returns 1 month after healing by second intent and commences treatment with the imiquimod, 5%, cream 5 d/wk and is reevaluated at 4-week intervals. If no inflammation is observed, we add tazarotene, 0.1%, gel on the weekends. After a patient reaches the intended treatment duration of 3 months, we allow the inflammation to resolve for an additional 8 weeks and then perform a conservative staged excision using 2-mm margins around the perimeter of the original tumor outline.

In our opinion, the benefits of this approach greatly outweigh the risks. First, surgical defect sizes may be markedly reduced based on the fact that most patients pretreated with imiquimod have negative histologic margins using 2-mm excisions, while less than 50% of patients not pretreated with imiquimod have negative histologic margins using 5-mm excisions.[3] Second, from the perspective of the pathologist, excised LM margins treated with imiquimod are much easier to interpret because atypical junctional melanocytic hyperplasia, characteristic of skin with chronic sun exposure, is largely eliminated and renders margin assessment less ambiguous. We like to use positive and negative control specimens when performing LM staged excisions. The positive control is a Melan-A immunostain on the original biopsy specimen, and we submit negative controls as previously reported,[17-19] usually from contralateral sun-exposed sites, which further reduces ambiguity in defining negative tumor margins (ie, when the LM excision is identical in melanocyte pattern and density to those of the negative control, we define that as a negative margin). To date, we have observed no recurrences in this patient cohort, with a mean follow-up period of 42 months. Previously published recurrence rates hover around 6% for staged excisions alone.[4,20-22] We would argue that the morbidity of standard staged excisions can be greatly reduced if the patient is pretreated with topical imiquimod before a staged excision, without undue added risk to the patient.

In a sense, the treatment approach we are using is a combination of surgery to remove the central tumor (saucerization of the entire visualized tumor at the initial visit) and topical imiquimod to eradicate residual atypical junctional melanocytic hyperplasia found at the perimeter. It has been well documented that concordance rates are fair at best among dermatopathologists reading LM margins for staged excisions,[17] so there is additional ambiguity that what we are calling LM may actually be a wide spectrum of lesions featuring atypical junctional melanocytic hyperplasia on sun-damaged skin that may or may not be melanoma biologically. Until we have molecular markers to identify those lesions that truly are destined to become invasive melanoma, the challenge remains to remove the tumors as conservatively as possible without unnecessarily disfiguring the patient, while eliminating as effectively as possible the cells that may progress to high-risk tumors.

Our study was conducted at a single institution among few surgeons and with a single Mohs surgeon (G.M.B.) reading the pathological results. It is possible that a larger sample size might have produced a more significant difference between the treatment groups. We acknowledge that LM recurrence can be delayed for many years. Therefore, we are keeping a vigilant watch on our patients treated with topical imiquimod and followed up by conservative staged excisions using 2-mm margins to ensure that conservative therapy is not placing them at undue risk for future recurrences.

©2012 American Medical Association. All rights reserved.
Downloaded From: http://archderm.jamanetwork.com/ on 06/19/2013

Accepted for Publication: January 21, 2012.
Published Online: March 19, 2012. doi:10.1001/archdermatol.2012.270
Correspondence: Mark A. Hyde, MMS, PA-C, Huntsman Cancer Institute, The University of Utah, 2000 Circle of Hope, Ste 2281, Salt Lake City, UT 84112 (Mark.hyde@hci.utah.edu).
Author Contributions: Mr Hyde and Dr Bowen had full access to all the data in the study and take responsibility for the integrity of the data and the accuracy of the data analysis. *Study concept and design:* Hadley, Tristani-Firouzi, and Bowen. *Acquisition of data:* Hyde, Hadley, Tristani-Firouzi, and Bowen. *Analysis and interpretation of data:* Hyde, Goldgar, and Bowen. *Drafting of the manuscript:* Hyde and Bowen. *Critical revision of the manuscript for important intellectual content:* Hyde, Hadley, Tristani-Firouzi, and Bowen. *Statistical analysis:* Hyde and Goldgar. *Administrative, technical, or material support:* Hyde and Bowen. *Study supervision:* Bowen.
Financial Disclosure: None reported.
Additional Information: The full study protocol is available from the corresponding author.

REFERENCES

1. Rapini RP, Bolognia JL, Jorizzo JL. *Dermatology.* Vol 2. St Louis, MO: Mosby; 2003:1789-1815.
2. Dhawan SS, Wolf DJ, Rabinovitz HS, Poulos E. Lentigo maligna: the use of rush permanent sections in therapy. *Arch Dermatol.* 1990;126(7):928-930.
3. Agarwal-Antal N, Bowen GM, Gerwels JW. Histologic evaluation of lentigo maligna with permanent sections: implications regarding current guidelines. *J Am Acad Dermatol.* 2002;47(5):743-748.
4. Bub JL, Berg D, Slee A, Odland PB. Management of lentigo maligna and lentigo maligna melanoma with staged excision: a 5-year follow-up. *Arch Dermatol.* 2004;140(5):552-558.
5. Hazan C, Dusza SW, Delgado R, Busam KJ, Halpern AC, Nehal KS. Staged excision for lentigo maligna and lentigo maligna melanoma: a retrospective analysis of 117 cases. *J Am Acad Dermatol.* 2008;58(1):142-148.
6. Farshad A, Burg G, Panizzon R, Dummer R. A retrospective study of 150 patients with lentigo maligna and lentigo maligna melanoma and the efficacy of radiotherapy using Grenz or soft X-rays. *Br J Dermatol.* 2002;146(6):1042-1046.
7. Iyer S, Goldman M. Treatment of lentigo maligna with combination laser therapy: recurrence at 8 months after initial resolution. *J Cosmet Laser Ther.* 2003;5(1):49-52.
8. Kuflik EG, Gage AA. Cryosurgery for lentigo maligna. *J Am Acad Dermatol.* 1994;31(1):75-78.
9. Sober AJ, Chuang TY, Duvic M, et al; Guidelines/Outcomes Committee. Guidelines of care for primary cutaneous melanoma. *J Am Acad Dermatol.* 2001;45(4):579-586.
10. Geisse J, Caro I, Lindholm J, Golitz L, Stampone P, Owens M. Imiquimod 5% cream for the treatment of superficial basal cell carcinoma: results from two phase III, randomized, vehicle-controlled studies. *J Am Acad Dermatol.* 2004;50(5):722-733.
11. Prinz BM, Hafner J, Dummer R, Burg G, Bruswanger U, Kempf W. Treatment of Bowen's disease with imiquimod 5% cream in transplant recipients. *Transplantation.* 2004;77(5):790-791.
12. Ahmed I, Berth-Jones J. Imiquimod: a novel treatment for lentigo maligna. *Br J Dermatol.* 2000;143(4):843-845.
13. Fleming CJ, Bryden AM, Evans A, Dawe RS, Ibbotson SH. A pilot study of treatment of lentigo maligna with 5% imiquimod cream. *Br J Dermatol.* 2004;151(2):485-488.
14. Naylor MF, Crowson N, Kuwahara R, et al. Treatment of lentigo maligna with topical imiquimod. *Br J Dermatol.* 2003;149(suppl 66):66-70.
15. Cotter MA, McKenna JK, Bowen GM. Treatment of lentigo maligna with imiquimod before staged excision. *Dermatol Surg.* 2008;34(2):147-151.
16. Bricca GM, Brodland DG, Zitelli JA. Immunostaining melanoma frozen sections: the 1-hour protocol. *Dermatol Surg.* 2004;30(3):403-408.
17. Florell SR, Boucher KM, Leachman SA, et al. Histopathologic recognition of involved margins of lentigo maligna excised by staged excision: an interobserver comparison study. *Arch Dermatol.* 2003;139(5):595-604.
18. McKenna JK, Florell SR, Goldman GD, Bowen GM. Lentigo maligna/lentigo maligna melanoma: current state of diagnosis and treatment. *Dermatol Surg.* 2006;32(4):493-504.
19. Bowen AR, Thacker BN, Goldgar DE, Bowen GM. Immunohistochemical staining with Melan-A of uninvolved sun-damaged skin shows features characteristic of lentigo maligna. *Dermatol Surg.* 2011;37(5):657-663.
20. Walling HW, Scupham RK, Bean AK, Ceilley RI. Staged excision versus Mohs micrographic surgery for lentigo maligna and lentigo maligna melanoma. *J Am Acad Dermatol.* 2007;57(4):659-664.
21. Bene NI, Healy C, Coldiron BM. Mohs micrographic surgery is accurate 95.1% of the time for melanoma in situ: a prospective study of 167 cases. *Dermatol Surg.* 2008;34(5):660-664.
22. Lee MR, Ryman WJ. Treatment of lentigo maligna with total circumferential margin control using vertical and horizontal permanent sections: a retrospective study. *Australas J Dermatol.* 2008;49(4):196-201.

©2012 American Medical Association. All rights reserved.
Downloaded From: http://archderm.jamanetwork.com/ on 06/19/2013