ONLINE FIRST

Calcium Hydroxylapatite Nodule Resolution After Fractional Carbon Dioxide Laser Therapy

Kavitha K. Reddy, MD; Jeremy A. Brauer, MD; Robert Anolik, MD; Leonard Bernstein, MD; Lori A. Brightman, MD; Elizabeth Hale, MD; Julie Karen, MD; Elliot Weiss, MD; Roy G. Geronemus, MD

Background: Injection of calcium hydroxylapatite filler may result in nodule formation owing to superficial placement of the filler. Calcium hydroxylapatite nodules are difficult to reverse. Previously reported therapeutic options are limited and include intralesional triamcinolone, massage, needling, and excision, each with inconsistent results or potential for scarring.

Observation: We have observed complete resolution of calcium hydroxylapatite nodules after a single treatment with fractional carbon dioxide laser.

Conclusions: A single session of fractional carbon dioxide laser treatment may resolve selected cases of calcium hydroxylapatite nodules. The mechanism of action may involve conversion of the product into tricalcium phosphates which dissolve readily. This novel therapeutic technique may enhance treatment options for a difficult clinical problem.

Arch Dermatol. 2012;148(5):634-636.
Published online February 20, 2012.
doi:10.1001/archdermatol.2011.3374

Author Affiliations: Laser & Skin Surgery Center of New York, New York, New York.

Injectable calcium hydroxylapatite (CaHA), a semipermanent filler approved by the US Food and Drug Administration for correction of moderate to deep nasolabial folds and for signs of lipoatrophy in individuals affected by human immunodeficiency virus, consists of 30% synthetic CaHA microspheres in a 70% aqueous gel vehicle.[1] Synthetic CaHA is identical to physiologic CaHA found in bones and teeth. In soft tissue, injected CaHA particles act as a scaffold for neocollagenesis and are slowly catabolized into calcium and phosphate ions cleared by metabolic processes.[2] Calcium hydroxylapatite volume correction has been reported to persist for an average of 1 to 1.5 years, with variable longevity thereafter.[1] In clinical practice, the filler has been used to treat a variety of sites of facial volume loss, including infraorbital volume loss.[1,3,4]

Common and transient adverse effects of CaHA include redness, swelling, itching, and bruising.[5] More persistent nodule formation has been observed, resulting most often from superficial placement of the filler.[1,6] Other rare causes of nodule formation may include CaHA migration[7] or granuloma formation.[8,9] To our knowledge, there have been no reports of osteoinduction.[10] In a series of 1000 patients treated with injectable CaHA and followed for more than 4 years, a 1.7% incidence of nodule formation was observed, most commonly at the lips.[1] The rate of nodule formation decreased as investigator experience increased, suggesting that the nodules were the result of overly superficial placement technique. The orbital area is also highly prone to "speed bump–like nodules," dependent on investigator experience.[4] It has been suggested that deep subdermal injection just above periosteum, filler placement in fine linear threads as opposed to bolus placement, and massage after placement may reduce the incidence of nodule formation.[1] Calcium hydroxylapatite nodules present a therapeutic challenge, with previously reported treatment methods including massage, 22-gauge needle disruption, intralesional triamcinolone, excision, and in some cases observation alone having been attempted with varied and often inconsistent results.[4,8,11] We report a case of a CaHA nodule that rapidly and completely resolved after fractional carbon dioxide laser treatment.

REPORT OF A CASE

A 42-year-old woman presented for treatment of bilateral lower eyelid laxity and was noted to have a yellowish-orange

©2012 American Medical Association. All rights reserved.
Downloaded From: http://archderm.jamanetwork.com/ on 05/25/2013

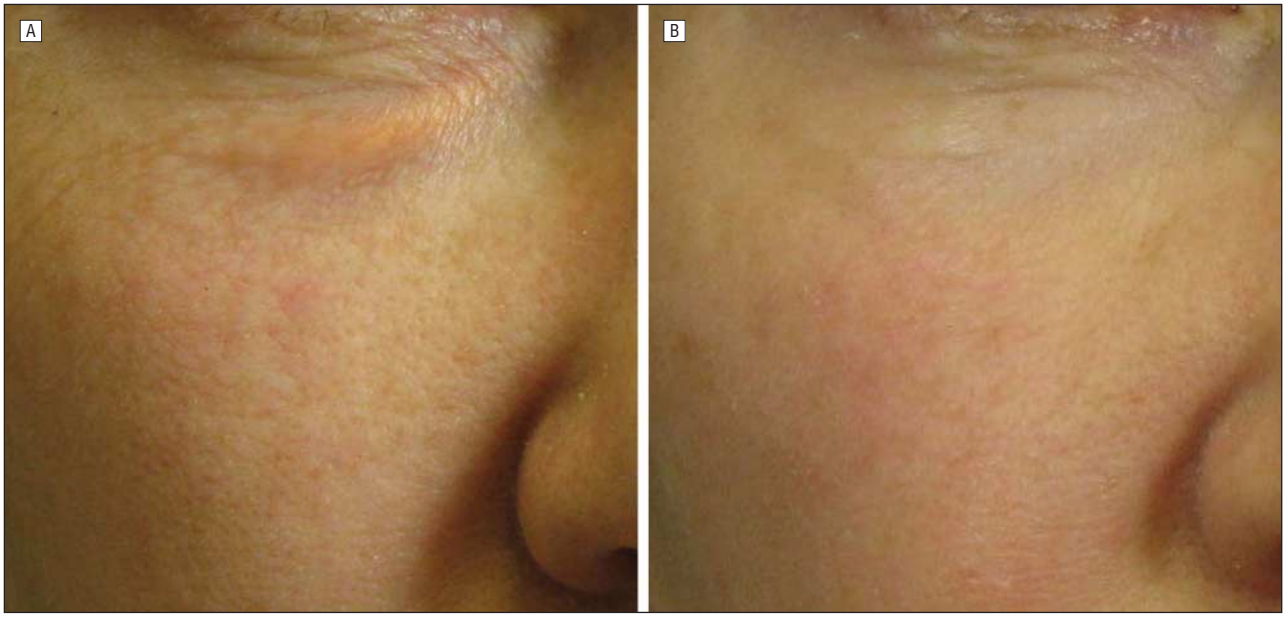

Figure. Calcium hydroxylapatite (CaHA) nodule. A, CaHA nodule at the right nasojugal fold. B, Resolution of CaHA nodule observed 2 weeks after single treatment with fractional carbon dioxide laser.

plaque at the right nasojugal fold (**Figure**). She reported that the plaque had developed immediately after infraorbital CaHA injection 6 months prior. The clinical diagnosis was CaHA nodule. The patient was treated for lower eyelid laxity with fractional carbon dioxide laser to the bilateral infraorbital skin, using a 135-μm handpiece at 30 mJ energy and treatment level 8 (30% coverage), with total energy delivered of 0.52 kJ. Per our normal protocol, 7% lidocaine–7% tetracaine cream was applied prior to the procedure, and prednisone 60 mg by mouth and toradol 30 mg by intramuscular injection were given before the procedure. The patient tolerated the treatment well, with mild erythema and edema after the procedure. Two weeks after treatment, the patient returned for a follow-up visit. Nodule resolution was observed, along with improvement in lower eyelid laxity (Figure). The patient has been followed for 2.5 years and has maintained excellent results without recurrence of the nodule.

COMMENT

Calcium hydroxylapatite filler has a variety of advantages, including semipermanent effect, good "value" owing to improved volume correction for an equal amount of filler compared with hyaluronic acid fillers, lack of allergy formation, and rare granuloma formation. Nodule formation, though less common with greater investigator experience, remains a potential adverse effect that may bring about hesitation to use CaHA filler as a result of inconsistent or poor results with current methods of treatment. Use of fractional carbon dioxide laser to quickly and successfully induce nodule resolution may represent a promising therapeutic option.

The CaHA nodule resolution observed is hypothesized to be the result of dissolution of CaHA particles by the fractional ablative carbon dioxide laser. To our knowledge, effects of carbon dioxide laser on injectable CaHA filler have not been reported in human skin; however, studies have described dissolution of CaHA particles after carbon dioxide laser treatment in other settings.[12-14] Investigation of the effect of carbon dioxide laser irradiation (10 600 nm, 2 W, 10 J, 0.2 seconds, 25 pulses) on dentinal surface (physiologic CaHA) revealed changes seen by electron microscopy, including charring, cratering, poring, fissuring, fracturing, cracking, and melting.[12] Particle-induced x-ray emission revealed decreased calcium content and increased phosphorus content, believed to be due to vaporization of CaHA crystals during carbon dioxide laser treatment. It was hypothesized that carbon dioxide laser treatment results in high-temperature vaporization of CaHA, with localized melting and rehardening into an α-calcium orthophosphate structure that displays increased brittleness with easy cracking and fissuring into multiple pieces.[12] Another investigation studied the effect of carbon dioxide, Nd:YAG, or carbon dioxide–Nd:YAG combination laser treatment at high fluences of 500 to 3230 J/cm^2 on synthetic CaHA.[13] Electron microscopy with x-ray diffraction again revealed CaHA conversion to α-tricalcium phosphate, which displays higher solubility than CaHA and dissolves more rapidly.[13] A third study using Q-switched Nd:YAG irradiation of dentin also resulted in recrystallization to tricalcium phosphates.[14] Other studies have shown similar cracks, photoacoustic disruption, and ablation of dentin after 193-nm excimer laser treatment, suggesting that direct excimer laser treatment may also potentially disrupt CaHA particles.[12,15-18]

The effect of other procedural therapies on CaHA has been studied in a limited fashion. Massage, needle disruption, intralesional triamcinolone, excision, and observation have been used with limited success.[4,8,11] Nonablative laser procedures are safe over CaHA-filled areas and do not seem to alter the longevity of CaHA filler.[10] Radio-

©2012 American Medical Association. All rights reserved.
Downloaded From: http://archderm.jamanetwork.com/ on 05/25/2013

frequency devices used over CaHA-treated areas have also been shown not to cause disruption or migration of the filler.[19] Fractional ablative laser treatment may provide a safe and effective option for nodule resolution in selected patients. Caution is advised in patients with darker skin types. Further studies are encouraged of this promising observed effect of fractional ablative carbon dioxide laser on CaHA nodules.

Accepted for Publication: December 16, 2011.
Published Online: February 20, 2012. doi:10.1001/archdermatol.2011.3374
Correspondence: Kavitha K. Reddy, MD, Laser & Skin Surgery Center of New York, 317 E 34th St, New York, NY 10016 (kreddy@laserskinsurgery.com).
Author Contributions: Drs Reddy and Geronemus had full access to the all of the data in the case described and take responsibility for the integrity of the data and the accuracy of data reporting and analysis. *Study concept and design:* Hale and Geronemus. *Acquisition of data:* Reddy and Brauer. *Analysis and interpretation of data:* Brauer, Anolik, Bernstein, Brightman, Karen, Weiss, Geronemus, and Reddy. *Drafting of the manuscript:* Reddy. *Critical revision of the manuscript for important intellectual content:* Reddy, Brauer, Anolik, Bernstein, Brightman, Hale, Karen, Weiss, and Geronemus. *Study supervision:* Geronemus.
Financial Disclosure: Dr Brightman has received honoraria from Solta Medical and Reliant. Dr Hale has stock ownership or options in Sanofi-Aventis, Allergan, Guthy-Renker, and Merck. Dr Weiss has been a consultant for Lithera. Dr Geronemus has been an investigator for Solta Medical.

REFERENCES

1. Tzikas TL. A 52-month summary of results using calcium hydroxylapatite for facial soft tissue augmentation. *Dermatol Surg*. 2008;34(suppl 1):S9-S15.
2. Marmur ES, Phelps R, Goldberg DJ. Clinical, histologic and electron microscopic findings after injection of a calcium hydroxylapatite filler. *J Cosmet Laser Ther*. 2004;6(4):223-226.
3. Vagefi MR, McMullan TF, Burroughs JR, White GL Jr, McCann JD, Anderson RL. Injectable calcium hydroxylapatite for orbital volume augmentation. *Arch Facial Plast Surg*. 2007;9(6):439-442.
4. Jacovella PF. Use of calcium hydroxylapatite (Radiesse) for facial augmentation. *Clin Interv Aging*. 2008;3(1):161-174.
5. Sadick NS, Katz BE, Roy D. A multicenter, 47-month study of safety and efficacy of calcium hydroxylapatite for soft tissue augmentation of nasolabial folds and other areas of the face. *Dermatol Surg*. 2007;33(suppl 2):S122-S126.
6. Flaharty P. Radiance *Facial Plast Surg*. 2004;20(2):165-169.
7. Goulart JM, High WA, Goldenberg G. Evidence of calcium hydroxylapatite migration: distant nodule formation in the setting of concurrent injection with nonanimal stabilized hyaluronic acid. *J Am Acad Dermatol*. 2011;65(2):e65-e66.
8. Jansen DA, Graivier MH. Evaluation of a calcium hydroxylapatite-based implant (Radiesse) for facial soft-tissue augmentation. *Plast Reconstr Surg*. 2006;118(3)(suppl):22S-33S.
9. Sankar V, McGuff HS. Foreign body reaction to calcium hydroxylapatite after lip augmentation. *J Am Dent Assoc*. 2007;138(8):1093-1096.
10. Lizzul PF, Narurkar VA. The role of calcium hydroxylapatite (Radiesse) in nonsurgical aesthetic rejuvenation. *J Drugs Dermatol*. 2010;9(5):446-450.
11. Cohen JL. Understanding, avoiding, and managing dermal filler complications. *Dermatol Surg*. 2008;34(suppl 1):S92-S99.
12. González M, Banderas JA, Rodríguez V, Castaño VM. Particle-induced X-ray emission and scanning electron microscopic analyses of the effects of CO_2 laser irradiation on dentinal structure. *J Dent*. 1999;27(8):595-600.
13. Meurman JH, Voegel JC, Rauhamaa-Mäkinen R, et al. Effects of carbon dioxide, Nd:YAG and carbon dioxide-Nd:YAG combination lasers at high energy densities on synthetic hydroxyapatite. *Caries Res*. 1992;26(2):77-83.
14. Rohanizadeh R, LeGeros RZ, Fan D, Jean A, Daculsi G. Ultrastructural properties of laser-irradiated and heat-treated dentin. *J Dent Res*. 1999;78(12):1829-1835.
15. Neev J, Liaw LH, Raney DV, Fujishige JT, Ho PD, Berns MW. Selectivity, efficiency, and surface characteristics of hard dental tissues ablated with ArF pulsed excimer lasers. *Lasers Surg Med*. 1991;11(6):499-510.
16. Stabholz A, Neev J, Liaw LH, Stabholz A, Khayat A, Torabinejad M. Effect of ArF-193 nm excimer laser on human dentinal tubules: a scanning electron microscopic study. *Oral Surg Oral Med Oral Pathol*. 1993;75(1):90-94.
17. Lustmann J, Ulmansky M, Fuxbrunner A, Lewis A. Photoacoustic injury and bone healing following 193nm excimer laser ablation. *Lasers Surg Med*. 1992;12(4):390-396.
18. Srinivasan R. Ablation of polymers and biological tissue by ultraviolet lasers. *Science*. 1986;234(4776):559-565.
19. Alam M, Levy R, Pajvani U, et al. Safety of radiofrequency treatment over human skin previously injected with medium-term injectable soft-tissue augmentation materials: a controlled pilot trial. *Lasers Surg Med*. 2006;38(3):205-210.

©2012 American Medical Association. All rights reserved.
Downloaded From: http://archderm.jamanetwork.com/ on 05/25/2013