who needed a dermatology consult took digital photographs and e-mailed them along with a brief history to a single e-mail address at a monitored server. The e-mails were then distributed to the on-call consulting dermatologists. More than 40 military dermatologists answered the consults on a rotating basis in a "team call" approach. The percentage of total consults and diagnostic agreement between primary care provider and dermatologist were calculated. In addition, the number of other comments by the call team was determined.

For the cost calculation, intertheater transfer of a patient to be evaluated by a dermatologist in Iraq was estimated to be $4000, while the cost of evacuation to the United States was estimated to be $14 082 (including the cost of lost duty days, ground transportation, airlift via helicopters and other aircraft, extra personnel required for security and transportation crews, and housing of patients during their evaluation and treatment).[4]

Results. A total of 2197 consults generated between January 2005 and January 2009 were reviewed. The most prevalent diagnoses by the consultant dermatologists were eczema (13%, n=285), fungal infection (7%, n=153), and bacterial infection (7%, n=152). There was a 34.4% diagnostic agreement between the provisional diagnosis of the primary health care provider and the teledermatology consultant. The most common diagnoses that the referring health care providers were able to correctly identify were smallpox vaccination reactions (59%) and leishmaniasis (75%). In total, 75.3% of the consults could be answered with a single definitive diagnosis by the dermatologist (n=1655), and 24.7% of the consults were answered with a differential diagnosis (n=542). Additional comments were provided in 18% of the single definitive diagnosis group (n=297) and 73% of the differential diagnosis group (n=395). A total of 1.4% of the consults recommended evacuation back to the United States (n=40), for an estimated cost of $562 380; 4.7% of patients were referred for in-person evaluation by the dermatologist in Iraq (n=104) for a cost of approximately $416 000.

Comment. Historically, primary health care providers provide most of the dermatologic care in a wartime environment.[1] Dermatologists in the military remain in short supply. Because of the high demand and low availability of dermatologists, teledermatology is an excellent specialist extender that allows primary health care providers worldwide access to dermatology consults.[3]

Currently, dermatology accounts for 31% of all telemedicine consults initiated by the US Army's telemedicine consult service.[5] One of the unique features of this program is that all of the dermatologists on the call team see the original question and response. Once the consult has been answered, the other members of the team are free to reply to the on-call dermatologist with additional thoughts. The original consultant then compiles the secondary comments and forwards these to the originating provider. This allows for an "instant quality control" aspect to this system. More additional comments were received when the on-call dermatologist replied with a differential diagnosis than when the reply specified a single definitive diagnosis.

A total of 2157 patients could be managed in Iraq, which is an overall cost savings of approximately 30.4 million dollars. One additional benefit of teledermatology in the combat setting is the incalculable savings of avoiding the risk of travel in a war zone.

This study demonstrates the role and cost savings of teledermatology in the combat setting. Dermatologic conditions remain a common complaint among deployed soldiers, and teledermatology can substantially reduce the number of patients who need to be evacuated for treatment, resulting in substantial cost savings.

J. Scott Henning, DO
Wendi Wohltmann, MD
Chad Hivnor, MD

Accepted for Publication: January 14, 2010.
Author Affiliations: Department of Dermatology, San Antonio Military Medical Center, San Antonio, Texas.
Correspondence: Dr Henning, 59 MDOS/SG05D/Dermatology, 2200 Bergquist Dr, Ste 1, Lackland AFB, TX 78236-9908 (jeffrey.henning@lackland.af.mil).
Author Contributions: All authors had full access to all of the data in the study and take responsibility for the integrity of the data and the accuracy of the data analysis. *Study concept and design:* Henning and Wohltmann. *Acquisition of data:* Henning. *Analysis and interpretation of data:* Henning, Wohltmann, and Hivnor. *Drafting of the manuscript:* Henning and Wohltmann. *Critical revision of the manuscript for important intellectual content:* Henning, Wohltmann, and Hivnor. *Statistical analysis:* Henning and Wohltmann. *Administrative, technical, and material support:* Henning, Wohltmann, and Hivnor. *Study supervision:* Henning, Wohltmann, and Hivnor.
Financial Disclosure: None reported.

1. Schissel DJ, Wilde J. Operational dermatology *Mil Med.* 2004;169(6):444-447.
2. Burgiss SG, Julius CE, Watson HW, Haynes BK, Buonocore E, Smith GT. Telemedicine for dermatology care in rural patients. *Telemed J.* 1997;3(3):227-233.
3. Pak HS, Welch M, Poropatich R. Web-based teledermatology consult system: preliminary results from the first 100 cases. *Stud Health Technol Inform.* 1999;64:179-184.
4. Mansuy JL. Direct aeromedical evacuation from USCENTCOM to the continental United States: a new direction for A/E? http://docs.google.com/viewer?a=v&q=cache:omeiMeW_sekJ:https://www.afresearch.org/skins/rims/q_mod_be0e99f3-fc56-4ccb-8dfe-670c0822a153/q_act_downloadpaper/q_obj_d3ce3175-a715-4cb6-815b-087939aec2a4/display.aspx%3Frs%3Denginespage+Direct+Aeromedical+Evacuation+from+USCENTCOM+to+the+Continental+United+States&hl=en&gl=us&rpid=bl&srcid=ADGEESgXDF-NENxtrPqLLuMxXj-4XIEaJ53N6m1RMfiEUz1zQZu8A1t0pLnfvV2fkNedPR-06ebtthfnCNDaq5is0XZCxtjxj5_Cy_fgUaaARcGT1gQelDttvxEnyRk_R46P11cqtXYB&sig=AHIEtbSTNOc5vFSafvEFEURr4s7Fx_g18w. Accessed January 12, 2010.
5. McGraw TA, Norton SA. Military aeromedical evacuations from central and southwest Asia for ill-defined dermatologic diseases. *Arch Dermatol.* 2009;145(2):165-170.

A Potential Association Between Alopecia Areata and Narcolepsy

To our knowledge, narcolepsy was first associated with alopecia areata (AA) in the Spanish-language literature in 1992.[1] The author described 2 patients with alopecia universalis and 1 with AA who subsequently developed symptoms suggestive of narcolepsy. In all 3 cases, the diagnosis of narcolepsy was made

©2010 American Medical Association. All rights reserved.
Downloaded From: http://archderm.jamanetwork.com/ on 05/23/2013

Table. 5 Cases of Alopecia Areata and Narcolepsy

Patient No.	Description
1[1]	An 18-year-old man with AU had complaints of diurnal somnolence; sudden weakness in the knees, neck, and arms; automatic behavior; and the appearance of nocturnal shaking. Evaluation via MSLT demonstrated 3 periods of SOREM. Other sleep disturbances were ruled out. A PSG evaluation was not documented.
2[1]	A 54-year-old woman with AA had complaints of diurnal somnolence; worsening memory; asthenia; frequent naps; automatic behavior; dreamlike activity; sleep paralysis; and sudden weakness in the knees, neck, arms, and mandible in emotional situations. Evaluation via MSLT showed 5 periods of SOREM, with a median latency time to sleep of 1.6 min. Other sleep disturbances were ruled out. A PSG evaluation was not documented.
3[1]	A 39-year-old man with AU had complaints of difficulty sleeping and asthenia since age 19 years after a stressful life event. He described frequent awakenings; hypersomnolence; automatic behaviors; dreamlike activity during naps; sleep paralysis; episodes of sudden weakness in the knees, neck, arms, and mandible; and hypnagogic hallucinations. The MSLT showed 5 periods of SOREM. A PSG evaluation was not documented.
4 (Present case 1)	A 19-year-old African American woman developed AA over a 1-year period that progressed to AT and finally to AU. At age 16 years, she had developed excessive daytime sleepiness but no sleep-onset insomnia, somniloquy, somnambulism, paroxysmal nocturnal dyspnea, palpitations, or reflux symptoms at night. No symptoms to suggest cataplexy, hypnagogic hallucinations, or sleep paralysis were clearly identified. She had asthma, allergic rhinitis, cyclic vomiting syndrome, and a severely reduced mandible, but no macroglossia or uvular or peritonsillar abnormalities and no family history of narcolepsy. Her thyroid function and neurologic findings were normal. Baseline PSG and MSLT results showed no evidence of substantial sleep apnea; diminished stage II or REM sleep; or oxygen desaturation of clinical consequence. She had no parasomnias or snoring, and she had normal sinus rhythm. Later MSLT results revealed pathologic sleepiness with a mean sleep latency period of more than 7 minutes and 2 short REM periods consistent with narcolepsy. The patient was started on modafinil therapy in November 2005 and remained on this therapy at last follow-up with a good response and no noted adverse effects, but she developed occasional sleep paralysis 18 months after beginning modafinil therapy.
5 (Present case 2)	A 20-year-old Asian American woman with chronically active patchy AA involving the scalp and lateral eyebrows of 2 years' duration developed narcolepsylike symptoms of daytime somnolence, nodding off while driving, difficulty concentrating, fatigue, irritability, and decreased academic and athletic performance. Her father had a history of undocumented sleep apnea. Baseline PSG results showed normal sleep efficiency and latency but reduced REM sleep latency. The MSLT findings were consistent with narcolepsy, and the patient was started on modafinil therapy.

Abbreviations: AA, alopecia areata; AT, alopecia totalis; AU, alopecia universalis; MSLT, multiple sleep latency test; PSG, polysomnography; REM, rapid eye movement; SOREM, sleep-onset REM.

with the multiple sleep latency test (MSLT), which is considered 1 of 2 confirmatory tests for narcolepsy, the other being polysomnography (PSG). To our knowledge, this association has not since been described.

We report herein 2 additional cases of AA in connection with narcolepsy seen in the Vanderbilt Dermatology Alopecia Clinic. These cases were observed by chance, and our report is meant only to add to the literature so that a possible association between the 2 likely autoimmune disorders is not overlooked.

Report of Cases. *Case 1.* A 19-year-old African American woman developed AA 3 years after a diagnostic MSLT revealed pathologic sleepiness. However, baseline PSG and MSLT had shown no evidence of clinically significant sleep apnea, diminished stage II or REM sleep, or clinically significant oxygen desaturation. She also had asthma, allergic rhinitis, and cyclic vomiting syndrome. The patient was started on modafinil treatment in November 2005 and continued that therapy at last follow-up, but she developed occasional sleep paralysis 18 months after modafinil treatment was begun.

Case 2. A 20-year-old Asian American woman with a 2-year history of chronically active AA involving the scalp and lateral eyebrows developed narcolepsylike symptoms of daytime somnolence: nodding off while driving, difficulty concentrating, fatigue, irritability, and decreased athletic and academic performance. The MSLT findings were consistent with narcolepsy, and the patient was started on modafinil therapy.

Comment. Narcolepsy is a sleep-wake disorder characterized by excessive daytime sleepiness, hypnagogic hallucinations, sleep paralysis and cataplexy, and/or sudden muscle weakness that results from a loss of hypothalamic neurons producing the neuropeptides orexin A and orexin B (hypocretin 1 and 2). An immunogenetic mechanism with a tight link with HLA allele *DQB1*0602* across ethnic groups has been established.[2] In patients heterozygous for *DQB1*0602*, an increased risk is conferred with *DQB1*0301*, especially in African Americans.[3] An autoimmune hypothesis for narcolepsy gained support with the recent discovery of a genetic link between narcolepsy and a gene encoding T-cell receptor alpha that interacts with HLA proteins to generate an immune response.[4]

Similar to other autoimmune diseases, AA is associated with particular major histocompatibility complex class II haplotypes that confer an increased risk, including *DQB1*03*, *DRB1*1104*, *DRB1*0401*, and *DQB1*0301*. The overlap in the *DQB1* regions in narcolepsy and AA suggests a concordance in patients with AA and narcolepsy that may link the 2 presumed autoimmune diseases in susceptible patients. In addition, CD200, which is expressed predominantly in outer root sheath follicular keratinocytes and may prevent undesired activation of autoreactive T cells,[5] was originally designated orexin 2. Orexins 1 and 2 are G protein–coupled receptors to which orexins A and B bind. The data from the 2 cases reported herein and the 3 taken from the literature[1] (**Table**) suggest, but do not prove, that there may be more than a random association of AA and narcolepsy occurring in some patients.

Lloyd E. King Jr, MD, PhD
Allyson W. Eastham, BS
Natalie M. Curcio, MD, MPH
Adriana N. Schmidt, MD

©2010 American Medical Association. All rights reserved.
Downloaded From: http://archderm.jamanetwork.com/ on 05/23/2013

Accepted for Publication: January 4, 2010.
Author Affiliations: Vanderbilt Dermatology Clinic, Vanderbilt University Medical Center, Nashville, Tennessee (Drs King, Curcio, and Schmidt); and University of Tennessee Health Science Center, Memphis (Ms Eastham).
Correspondence: Dr Schmidt, Vanderbilt Dermatology Clinic, Vanderbilt Health–One Hundred Oaks, 719 Thompson Ln, Ste 26300, Nashville, TN 37204 (adriana.schmidt99@gmail.com).
Author Contributions: Drs King and Schmidt had full access to all of the data in the study and take responsibility for the integrity of the data and the accuracy of the data analysis. *Study concept and design:* King and Schmidt. *Acquisition of data:* King, Eastham, and Curcio. *Analysis and interpretation of data:* King and Schmidt. *Drafting of the manuscript:* King, Eastham, and Schmidt. *Critical revision of the manuscript for important intellectual content:* King and Curcio. *Obtained funding:* King. *Administrative, technical, and material support:* King. *Study supervision:* King and Schmidt. *Translation of cited article from Spanish:* Curcio.
Financial Disclosure: None reported.

1. Domínguez Ortega L. Narcolepsy and alopecia areata: a new association? [in Spanish]. *An Med Interna.* 1992;9(5):234-236.
2. Pelin Z, Guilleminault C, Risch N, Grumet FC, Mignot E; US Modafinil in Narcolepsy Multicenter Study Group. HLA-DQB1*0602 homozygosity increases relative risk for narcolepsy but not disease severity in two ethnic groups. *Tissue Antigens.* 1998;51(1):96-100.
3. Mignot E, Lin L, Risch N, et al. Identification of a novel HLA narcolepsy susceptibility subtype, HLA DQB1*0301. *Sleep.* 1999;22(suppl 1):121-122.
4. Hallmayer J, Faraco J, Lin L, et al. Narcolepsy is strongly associated with the T cell receptor alpha locus. *Nat Genet.* 2009;41(6):708-711.
5. Rosenblum MD, Olasz EB, Yancey KB, et al. Expression of CD200 on epithelial cells of the murine hair follicle: a role in tissue-specific immune tolerance? *J Invest Dermatol.* 2004;123(5):880-887.

COMMENTS AND OPINIONS

Dirt-Adherent Dermatosis: Not Worth an Additional Name

I read with great interest the article by Shan et al[1] describing a patient with dirtlike lesions diagnosed as cutaneous dirt-adherent disease (CDAD).

Report of a Case. Recently, I saw a similar case: a 5-year-old boy with asymptomatic pigmented and keratotic lesions of 3 months' duration. His parents assured me that the child maintained good hygiene, showering once or twice daily with soap. He was healthy and took no medications.

Physical examination disclosed palpable, papillomatous, brown plaques on the scrotum and penis skin (**Figure 1**A). The lesions could be easily swabbed away with isopropyl alcohol (Figure 1B). Vigorous alcohol rubbing of all affected areas removed virtually all of the unusual lesions, confirming the diagnosis of terra firma–forme dermatosis (TFFD). Recrudescence was not observed during 6 months of follow-up. The patient's parents were satisfied to see such a cosmetically bothersome skin condition disappear with simple application of isopropyl alcohol.

Comment. Dirtlike lesions usually present both diagnostic and therapeutic challenges. Although they pose no hazard to the health, they are aesthetically bothersome and can cause severe distress. There is a consensus that a group of skin diseases is characterized by a pigmented and dirty appearance. Among them, dermatosis neglecta (DN) is the most common, a condition caused by chronic avoidance of washing. These lesions detach under routine rubbing with soap and a washcloth.[2]

Terra firma–forme dermatosis involves dirty patches that are unaffected by soap and water cleansing but can be removed by alcohol swabbing with substantial shearing force. A history of normal washing rules out DN and points toward TFFD.[3]

Confluent and reticulated papillomatosis (CARP) has a velvety and reticulated appearance. Commonly, it affects a patient's central trunk and is does not respond to cleansing or alcohol swabbing.[4] There are yet other skin disorders that should be put into this category.[5]

Cutaneous dirt-adherent disease is a general term that Chinese dermatologists preferentially apply if pigmented, keratotic lesions are present. In my opinion, it is a rather vague name and can now be more precisely diagnosed as DN, TFFD, CARP, or another skin disorder, provided that detailed clinical data are available. A retrospective review of the Chinese literature revealed 97 reports of CDAD cases since its first report in China in 1985. Among them, 4 can now be more precisely diagnosed as TFFD; 16 as DN; and 9 as head and neck *Malassezia* dermatosis. No revised diagnosis is possible in the remaining 68 cases owing to incomplete clinical data, but I believe that, given sufficient data, more precise diagnoses might be applied to them as well.

To eliminate the general diagnosis of CDAD and avoid unnecessary biopsies and expensive endocrinologic examinations in favor of alcohol-swabbing tests and water-washing tests, I propose the unifying stepwise approach to the diagnosis of dirtlike lesions outlined in **Figure 2**. Awareness of the differences among dirtlike skin disorders detailed in this flowchart could facilitate prompt diagnosis without the need to perform potentially expensive and unnecessary tests.

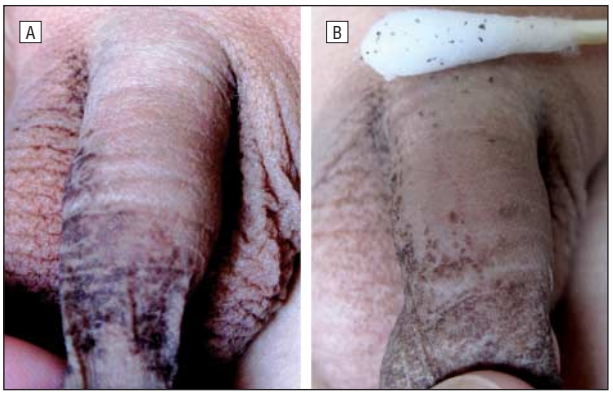

Figure 1. Clinical photographs of the patient. A, Extensive dirtlike lesions involving the penis skin and manifesting as reticular lesions on the scrotum. B, Alcohol swabbing reveals underlying normal skin.

©2010 American Medical Association. All rights reserved.
Downloaded From: http://archderm.jamanetwork.com/ on 05/23/2013