STUDY

The Forehead Flap for Nasal Reconstruction

Charles M. Boyd, MD; Shan R. Baker, MD; Darrell J. Fader, MD; Timothy S. Wang, MD; Timothy M. Johnson, MD

Context: Reconstruction of extensive nasal defects often represents a significant challenge owing to several unique qualities of the nose, such as complex topography, mobile free margins, and multiple nasal subunits. Furthermore, loss of internal nasal lining and/or structural skeletal support may be present following removal of extensive skin cancers.

Objective: To describe our experience with the use of forehead flap reconstruction for extensive nasal defects.

Design: Retrospective case series.

Setting: Academic health care hospital system.

Patients/Intervention: One hundred forty-seven patients with extensive nasal defects repaired with a forehead flap.

Main Outcome Measures: The functional and aesthetic results were assessed. The characteristics of defects repaired with the forehead flap and the need for lining and/or cartilage were examined.

Results: The forehead flap was used to repair 147 nasal defects after Mohs excision of nonmelanoma skin cancer. Full-thickness skin was lost in all cases, structural skeletal support in 68 cases (46%), and internal mucosal lining in 45 cases (31%). Our experience and surgical technique using the forehead flap are described.

Conclusions: The forehead flap represents one of the best methods for repair of extensive nasal defects. Near-normal functional and cosmetic results can be achieved.

Arch Dermatol. 2000;136:1365-1370

From the Departments of Dermatology (Drs Boyd, Fader, Wang, and Johnson), Otorhinolaryngology (Drs Boyd, Baker, Fader, and Johnson), and Surgery (Division of Plastic Surgery) (Dr Johnson), University of Michigan Health System and University of Michigan Comprehensive Cancer Center, Ann Arbor.

LARGE NASAL defects often provide a significant challenge to the reconstructive surgeon. The nose is characterized by several unique qualities, including complex topography, many mobile free margins, adjacent aesthetic subunits, and varying skin properties with respect to thickness, texture, color, and sebaceous content. A thorough understanding of anatomy, reconstructive options, tissue movement, and patient and defect considerations is necessary for optimal functional and aesthetic surgical reconstruction of the nose.[1] Collegial exchange of knowledge and experience between reconstructive specialties has resulted in many surgical approaches and better options and techniques to repair nasal defects. We describe a series of 147 patients using one approach, the forehead flap, for the repair of larger or cosmetically challenging defects of the nose.

COMMENT

HISTORY

The history of nasal reconstruction can be traced as far back as 600 to 700 BC in India. The first record of the operation appeared around 700 BC in an Indian medical treatise entitled *Susruta Samhita*.[2] Antonio Branca, of Italy, is credited with the first reported use of the midforehead flap outside of India.[3] Based on an Arabic translation, Branca performed the operation in the 15th century. The technique was still largely unknown to the Western World until J. C. Carpue read an editorial description of the technique that was published in the *Gentlemen's Gazette* in 1794.[4] Carpue practiced the technique on cadavers for 20 years, until he found the right patients. He then described 2 cases in a monograph entitled "An Account of Two Successful Operations for Restoring a Lost Nose."[5] His article, which was widely circulated, popularized the operation throughout Europe. The operation was first performed in America by J. M. Warren in the late 1830s.[6] In the 1930s and 1940s, a thorough understanding of the vascular anatomy was provided by Kazanjian,[7] who pioneered primary closure of the donor site. Further advances were made by Millard[6,8-10] in the 1960s and 1970s. He described a median forehead flap with lateral extensions that could be used to recreate the nasal ala and the use of internal lining. He was also one of the first authors to recommend placing the skeletal support for the nose before or at the time of soft tissue re-

©2000 American Medical Association. All rights reserved.
Downloaded From: http://archderm.jamanetwork.com/ on 05/19/2013

PATIENTS AND METHODS

One hundred forty-seven patients were identified from the University of Michigan, Ann Arbor, Mohs database from 1993 to 1999 whose nasal defects had been repaired using the forehead flap after Mohs excision of basal cell carcinoma (n=144) or squamous cell carcinoma (n=3). Defect sizes ranged from 1.0×1.0 to 5.0×5.6 cm (mean, 2.5×3.0 cm). While multiple nasal units were involved with defects, the tumor arose primarily on the nasal tip in 48 patients, on the ala in 47 patients, on the sidewall in 36 patients, and on the dorsum/bridge in 20 patients. Four patients had 2 lesions involving more than 1 nasal unit that were simultaneously treated. Full-thickness skin was lost in all cases, with significant loss of cartilage, muscle, and/or fibrofatty tissue in 68 cases (46%). Forty-five patients (31%) presented with full-thickness (including mucosa) defects. Fifty-one patients (35%) were men, and 96 (65%) were women. The men ranged in age from 34 to 84 years (mean age, 65 years); the women, from 29 to 92 years (mean age, 63 years).

Replacement of the internal nasal lining was required for through-and-through defects in 45 patients (31%) and was most commonly replaced with an intranasal septal hinge flap or a bipedicle mucosal flap. Structural support was necessary in 68 patients (46%). Support was accomplished with cartilage from the ear (n=41), nasal septum (n=6), septum and ear (n=17), septum and septal bone (n=2), septum and irradiated cartilage (n=1), and nasal cartilage during revision rhinoplasty (n=1). Secondary revisional procedures were performed in 79 patients (54%), with 1 revision in 56 patients, 2 revisions in 22 patients, and 3 revisions in 1 patient. Debulking of the flap was performed in 68 patients, dermabrasion in 40 patients, Z-plasty in 11 patients, revisional cartilage graft in 2 patients, and suspension suture for opening the nasal valve in 1 patient. High aesthetic and functional goals were achieved in all patients. No tumor recurrences or significant episodes of local bleeding or infection occurred in this population. There were no cases of significant flap necrosis. However, 2 patients (1%) developed mild superficial partial-thickness necrosis, which was thought to be related to a combination of length, thinning, and cautery for follicular destruction for columella reconstruction in one patient and to flap extension way past midline for an extensive defect in the other. Both healed uneventfully simply with granulation.

construction.[6] Previous authors often recommended that soft tissue reconstruction be performed first, which led to soft tissue contraction and prevented optimal skeletal reconstruction. The work of Burget and Menick[11] in the 1970s led to the understanding that by extending the incisions below the orbital rim, one did not have to curve the flap or extend it into the hairline to reach the nasal tip. They also discovered that the end arterioles of the supratrochlear artery travel just below the dermis, superficial to the frontalis muscle. This allowed removal of the frontalis muscle from the flap, thus improving the ability to contour the flap to the defect.[12,13] Menick[14] also described the paramedian forehead flap based on a single supratrochlear artery. This flap has a much narrower base than the median forehead flap. This design allowed the surgeon to increase the rotation and length of the flap. In 1985, Burget[13] and Menick[14] divided the nose into topographic subunits of dorsum, tip, columella, alae, sidewalls, and soft triangles. They achieved superior results by reconstructing and replacing the entire subunit instead of an isolated defect. Their textbook, which was published in 1994, became the "gold standard" for forehead flap and nasal reconstruction.[15] Other authors, such as Shumrick and Smith,[2] Mangold et al,[16] McCarthy et al,[17,18] and Baker and Swanson,[19] have continued to fine-tune the paramedian flap into what has now become a reliable, aesthetic, and versatile way to reconstruct the nose.

ANATOMY

The forehead region contains an intricate array of anastomosing vessels. Shumrick and Smith[2] performed detailed anatomical studies of the forehead vasculature using latex injection, microdissection, and radiographic data. They found anastomoses between the angular, supratrochlear, supraorbital, and superficial temporal arteries. The supratrochlear artery was found to consistently exit the superior medial orbit approximately 1.7 to 2.2 cm lateral to the midline, and continued its course vertically in a paramedian position approximately 2.0 cm lateral to the midline. This position corresponds to the location of the medial portion of the eyebrow. The supratrochlear artery pierces the orbital septum by traveling under the orbicularis oculi muscle and over the corrugator muscle. The supratrochlear artery is the primary axial blood supply of midforehead flaps, which include median and paramedian flaps.

A precise understanding of the anatomical basis of the forehead flap allows the surgeon to harvest a flap based on a narrower pedicle, which increases the length and rotation of the flap. The supratrochlear pedicle can be as narrow as 1.0 to 1.2 cm.[14,15,19,20] This narrow pedicle reduces donor site morbidity in the glabellar region. Since the paramedian forehead flap is based on just one of the supratrochlear arteries, a second forehead flap can be harvested at the same time or secondarily if needed. The work of Shumrick and Smith[2] also demonstrated that the end arterioles of the supratrochlear vessels travel superficial to the frontalis muscle in the upper third of the flap. This anatomical knowledge allows the surgeon to thin the flap considerably to achieve definition and precise contour of the various nasal subunits that it is used to cover.[19] Thinning the flap greatly decreases the need for revision surgery to debulk the flap. The excellent vascular supply of the flap also enables the surgeon to incorporate free cartilage or bone grafts into the primary reconstruction. The paramedian forehead flap usually provides non–hair-bearing skin with an excellent color and texture match for nasal reconstruction. Depending on the laxity of the patient's skin, flaps as wide as 4.5 cm can be harvested and the donor site closed primarily.[20,21] Since these are interpolation flaps, a second operation is needed to detach the pedicle from the flap. This procedure can be performed 10 to 14 days after transfer. However, we prefer an inter-

©2000 American Medical Association. All rights reserved.
Downloaded From: http://archderm.jamanetwork.com/ on 05/19/2013

Figure 1. *A 2.5 × 2.8-cm defect to the cartilage.*

Figure 2. *Forehead flap designed with a narrow pedicle based on the supratrochlear artery.*

val of 3 weeks, which provides time for the flap to achieve a rich collateral blood supply and facilitates further sculpting of the proximal portion of the flap.

SURGICAL TECHNIQUE

The forehead flap is a 2-stage procedure, and patients should receive preoperative counseling concerning their appearance between the first and second stages of the procedure. Thorough preoperative planning, including assessment of the defect, hairline height, and forehead laxity, is important. Patients should be given wound care instructions, and realistic goals about the final outcome of their nasal reconstruction.

The concept of "turf," and which specialty can or should perform forehead flap reconstruction, represents an unfortunate reality. Our multidisciplinary cutaneous oncology program is characterized by cooperation and participation from multiple disciplines, a genuine desire for interdisciplinary education and exchange, unbridled enthusiasm for new and better methods, and excellent patient care. In our program, performing a forehead flap is not limited by specialty but is a function of experience, desire, and judgment. It makes no difference who does the procedure, as long as it is done correctly.

Forehead flaps performed by the dermatologic surgery service (**Figures 1**, **2**, **3**, **4**, **5**, and **6**) are usually performed with the patient under local anesthesia alone, sometimes with the addition of oral or sublingual diazepam. These cases are generally limited to soft tissue defects with the nasal lining intact. Surgical procedures to treat complex defects that involve the use of lining, extended flap length, considerable size, and/or long procedure time, when it may be less comfortable for a patient who is awake, are performed at our institution with the patient under intravenous sedation or general anesthesia. Intravenous sedation or general anesthesia is also usually used for patients with significant anxiety or medical problems.

Figure 3. *Aggressive thinning of the distal two thirds for contour.*

The majority of our patients undergo forehead flap reconstructive surgery under intravenous sedation, consisting of a narcotic, such as fentanyl citrate, and a propofol drip. They are then locally anesthetized using 1% lidocaine with a 1:100 000 concentration of epinephrine and usually treated with a broad-spectrum prophylactic antibiotic of the surgeon's choice. Placing the patient in the supine position in approximately 20° to 30° of the reverse Trendelenburg position has the advantage of decreasing intraoperative bleeding by preventing venous pooling and flap congestion. For patients who are undergoing the proce-

©2000 American Medical Association. All rights reserved.
Downloaded From: http://archderm.jamanetwork.com/ on 05/19/2013

Figure 4. *Flap sutured in place.*

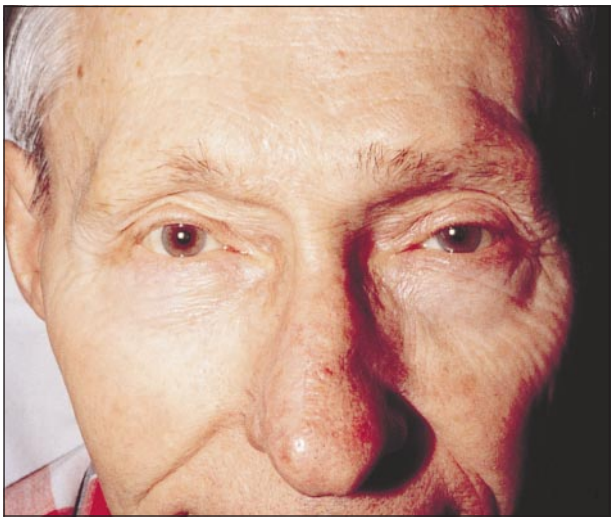

Figure 5. *Four-month postoperative result.*

dure with a local anesthetic, a straight supine position is easy and prevents a vasovagal response. The full face is prepared and draped in a sterile fashion. The principle involved is that of resurfacing all of a nasal subunit if the defect includes more than 50% of the surface area of the subunit.[22]

The subunit principle is based on the observation that the ridges and valleys of nasal contour create visual patterns of topographical regional units and subunits that reflect the contour of the underlying hard and soft tissues. The outline and definition of each subunit are determined by observing the light and shadow reflected from each individual nose. The subunits are defined by direct visual observation of surface contour, texture, color, and adnexal content and quality. These topographical subunits must be visualized and defined in the surgeon's mind during the planning and execution of reconstruction. Approximately 9 subunits exist on the nose.[13,15,22,23] Five are convex: the tip, dorsum, columella, and paired ala-nostril sills. Four are concave: the paired sidewalls and paired soft triangles. Using the subunit principle, the surgeon can select the best donor tissue match with respect to color, texture, thickness, and adnexal qualities. Also, the surgeon can control the size, shape, and position of incision lines and thus determine the location of the scars. By enlarging and/or altering defects to fit topographical subunits, the resulting scars will fall in borders of the subunits. As the scars fade with maturation, the shadows and reflections along the borders of the subunits successfully camouflage the scars. Scars are therefore usually less apparent when the subunit principle is used, because they fall within and along the borders of the subunits.

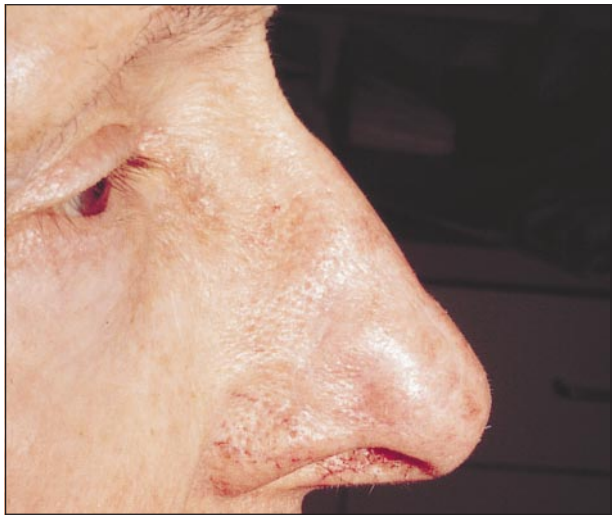

Figure 6. *Four-month postoperative result.*

Baker's[24] criteria for defect analysis are followed. A template of the corresponding nasal subunit, containing the defect, is made from surgical foam or from the foil of a suture pack. The flap can be designed using a Doppler probe to precisely locate the supratrochlear artery as it exits the superior medial orbit. This will allow narrowing of the pedicle to as little as 1.0 cm at the glabella. The pedicle may be designed on the contralateral or ipsilateral side of the primary nasal defect. Historically, a contralateral design was favored because it resulted in less torsion on the pedicle. However, a narrow pedicle, which is most commonly used at present, allows an ipsilateral design without concerns about for clinically significant torsion. We routinely use an ipsilateral pedicle, often extending it below the brow, which has the advantage of increased obtainable flap length. Then, the length of the flap is usually determined by measuring with gauze or a suture from the base of the pedicle to the tip of the flap template at the hairline. While the suture is held at the base of the pedicle, the remaining position is rotated 180° in the coronal plane to the distal recipient site on the nose. If the suture cannot reach this site, the template must be repositioned higher on the forehead or the pedicle base must be lowered below the level of the eyebrow. The flap is then precisely outlined on the forehead with a surgical marker as close to midline as the pedicle will allow. The right edge of the template must correspond to the left edge of the primary defect.

©2000 American Medical Association. All rights reserved.
Downloaded From: http://archderm.jamanetwork.com/ on 05/19/2013

Lidocaine (1%) with a 1:100 000 concentration of epinephrine is then injected into the skin surrounding the surgical defect and all the skin of the forehead, except near the pedicle base. The defect is debrided of nonviable tissue, and the margins are refined and extended to incorporate the subunit(s) with a scalpel. The flap is elevated together with the frontalis muscle along a cleavage plane superficial to the periosteum of the frontal bone. The flap is elevated from superior to inferior, with care being taken as the dissection reaches 1 to 2 cm above the eyebrow. Blunt dissection is then performed to avoid cutting the supratrochlear artery as it exits over the corrugator supercilii muscle. Once the artery has been identified and preserved, blunt dissection and sharp dissection are used to continue the dissection down to the root of the nose to achieve adequate flap length. Once the flap is elevated, it is pivoted 180° on its base. The flap is thinned by removing the distal frontalis muscle and subcutaneous fat to match the precise depth and breadth of the defect. Usually only the distal three fourths of the flap required for reconstruction is contoured at this time. The proximal one fourth is left thick until the pedicle is detached.

For large or tight donor defects, the donor site is closed by extensively undermining the forehead in a submuscular plane to the anterior borders of the temporalis muscle bilaterally. If needed, several parallel vertical galeotomies, 2 to 3 cm apart, are made to the level of the subcutaneous fat. The muscle and fascia are closed in a single layer with a 2-0, 3-0, or 4-0 absorbable suture, and the skin is closed with a 5-0 polypropylene (Prolene) suture. No drain is required. If needed, internal lining is replaced, usually with septal or bipedicle mucosal flaps. If required, skeletal and structural loss is reconstructed with donor cartilage from the ear or septum. The trimmed flap is inset into the primary defect on the nose using a 5-0 absorbable suture for the deep layers, and skin closure is achieved with a 5-0 or 6-0 polypropylene suture. Often, deep sutures are not used, and the skin is simply closed in a cutaneous vertical mattress interrupted fashion. Bupivacaine hydrochloride (Marcaine) (0.25%) may be infiltrated in the skin of the forehead after wound closure for postoperative pain relief. The raw undersurface of the exposed pedicle is left open or gently wrapped with petrolatum gauze, with care being taken not to constrict the pedicle.

Patients are discharged home after surgery or kept overnight for observation and wound care. It has been our experience that most patients who undergo extensive nasal reconstruction (**Figures 7**, **8**, **9**, and **10**) appreciate an overnight admission to aid in wound care and to ensure adequate intravenous hydration. Prescriptions at discharge include a broad-spectrum antibiotic, which is to be taken for 7 to 10 days. A mild pain reliever, such as acetaminophen (Tylenol) with codeine, and an antiemetic are often prescribed. Postoperative wound care consists of twice daily cleansing of the suture lines with hydrogen peroxide and application of an antibiotic ointment or petroleum jelly.

On the fifth to seventh postoperative day, the sutures are removed. The patient is scheduled for flap detachment approximately 3 weeks from the date of initial surgery. Pedicle separation is done with the patient under local anesthesia. The pedicle is separated sharply, and enough of the base of the pedicle is returned to the glabellar region to achieve a normal intereyebrow distance. Excess pedicle should not be returned to the forehead above the level of the eyebrows to enhance the cosmetic outcome. The proximal portion of the inset flap is thinned and contoured to reconstruct the nasal subunit. Deep closure is not necessary, since the wound should be under no tension. The skin is closed with a 5-0 or 6-0 polypropylene suture. Revision surgery, such as thinning of the flap, is usually delayed 3 to 6 months to allow complete wound healing, contracture, and beginning of scar maturity. Derm-

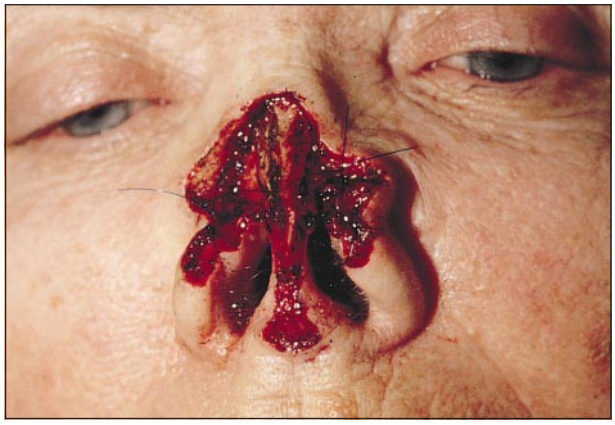

Figure 7. *Large full-thickness nasal defect following Mohs excision of a recurrent basal cell carcinoma.*

Figure 8. *Internal lining and skeletal support repaired with septal mucosal lining and cartilage grafts prior to forehead flap.*

Figure 9. *Six-month postoperative result.*

©2000 American Medical Association. All rights reserved.
Downloaded From: http://archderm.jamanetwork.com/ on 05/19/2013

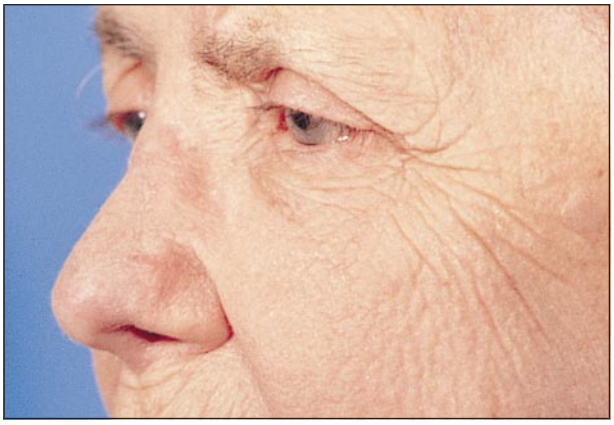

Figure 10. *Six-month postoperative result.*

abrasion of the flap and adjacent normal skin is usually performed 6 to 8 weeks after flap detachment. Our series highlights the principle of revision, which is defined by the desire to achieve the best aesthetic and functional result through continual revision and touch-up until that goal is reached. Fifty-four percent of our patients underwent at least 1 secondary revisional procedure.

One disadvantage of the paramedian forehead flap is the vertical forehead scar. The wound edges must be carefully approximated to minimize wound tension. For large secondary defects, we achieve this by widely undermining the forehead skin, to the temporalis muscle bilaterally. Additional length can be achieved by performing galeatomies on either side of the incision. Inability to achieve primary closure is not a contraindication to performing a forehead flap. Allowing the donor site to heal in part by secondary intention usually results in an acceptable cosmetic result. Another disadvantage of the paramedian forehead flap is its limited length in patients with low hairlines. Several modifications are possible, such as the oblique forehead flap, tissue expansion, or extension of the flap into hair-bearing scalp.[25] When it is necessary to include hair-bearing skin in the flap, the surgeon must meticulously thin the flap to remove the hair follicles at the time of transfer or pedicle division. Even meticulous thinning may not prevent all hair regrowth, and such options as serial fine-needle electrolysis or hair removal laser may be necessary and beneficial.

Potential complications with the use of the forehead flap for nasal reconstruction, which are similar to those involved in any flap reconstructive procedure, include bleeding, pain, poor scarring, infection, dehiscence, distortion of free margins, and flap necrosis. Patient selection, surgical planning and preplanning, and meticulous technique are all necessary to minimize potential complications.

CONCLUSIONS

The nose is one of the most common locations for skin cancer and frequently represents a significant challenge for reconstruction after surgical excision. Reconstruction of defects created by removal of cancer represents the secondary event in successful skin cancer treatment. Complete tumor extirpation, the primary event, is key. The best reconstructive effort eventually fails in the face of tumor recurrence. The forehead flap represents one of the best methods for repair of extensive nasal defects. Outstanding functional and cosmetic results can be achieved. Proper execution requires considerable technical skill and experience. Preoperative counseling is vitally important. Also, a thorough understanding of anatomy and aesthetics is required. Several pioneers and experts in modern forehead flap reconstruction from the disciplines of plastic, otolaryngological, and facial plastic surgery have graciously and openly helped to educate those of us in related fields, including dermatology, through many courses, lectures, and publications. This type of interdisciplinary collegiality and sharing of knowledge elevates all involved.

Accepted for publication July 10, 2000.

Corresponding author: Charles M. Boyd, MD, Department of Otorhinolaryngology, University of Michigan, 1904 Taubman Center, Box 0312, Ann Arbor, MI 48109-0312 (e-mail: cmboydmd@umich.edu).

REFERENCES

1. Johnson TM, Baker SR, Swanson N. Concepts of sliding and lifting tissue movement in flap reconstruction. *Dermatol Surg.* 2000;26:274-278.
2. Shumrick KA, Smith TL. The anatomic basis for the design of forehead flaps in nasal reconstruction. *Arch Otolaryngol Head Neck Surg.* 1992;118:373-379.
3. Mazzola RF, Marcus S. History of total nasal reconstruction with particular emphasis on the folded forehead flap technique. *Plast Reconstr Surg.* 1983; 72:408-414.
4. McDowell F. The "B.L." bomb-shell (B. Lucas). *Plast Reconstr Surg.* 1969;44: 67-73.
5. Carpue JC. An account of two successful operations for restoring a lost nose. *Plast Reconstr Surg.* 1969;44:175-182.
6. Millard DR. Total reconstructive rhinoplasty and a missing link. *Plast Reconstr Surg.* 1966;37:167-183.
7. Kazanjian VH. The repair of nasal defects with the median forehead flap: primary closure of the forehead wound. *Surg Gynecol Obstet.* 1946;83:37-42.
8. Millard DR. Reconstructive rhinoplasty for the lower half of a nose. *Plast Reconstr Surg.* 1974;53:133-139.
9. Millard DR. Reconstructive rhinoplasty for the lower two-thirds of the nose. *Plast Reconstr Surg.* 1976;57:722-728.
10. Millard DR. Hemirhinoplasty. *Plast Reconstr Surg.* 1967;40:440-445.
11. Burget GC, Menick FJ. Nasal reconstruction: seeking a fourth dimension. *Plast Reconstr Surg.* 1986;78:145-157.
12. Burget GC, Menick FJ. Nasal support and lining: the marriage of beauty and blood supply. *Plast Reconstr Surg.* 1989;84:189-203.
13. Burget GC. Aesthetic restoration of the nose. *Clin Plast Surg.* 1985;12:463-480.
14. Menick FJ. Aesthetic refinements in use of forehead for nasal reconstruction: the paramedian forehead flap. *Clin Plast Surg.* 1990;17:607-622.
15. Burget GC, Menick FJ. *Aesthetic Reconstruction of the Nose.* St Louis, Mo: Mosby–Year Book Inc; 1994.
16. Mangold U, Lierse W, Pfeifer G. The arteries of the forehead as the basis of nasal reconstruction with forehead flaps. *Acta Anat.* 1980;107:18-25.
17. McCarthy JG, Lorenc ZP, Cutting L, Rachesky M. The median forehead flap revisited: the blood supply. *Plast Reconstr Surg.* 1985;76:866-869.
18. McCarthy JG. Acquired deformities of the nose. In: *Plastic Surgery.* 3rd ed. Philadelphia, Pa: WB Saunders Co; 1990:1925-2005.
19. Baker SR, Swanson NA. *Local Flaps in Facial Reconstruction.* St Louis, Mo: Mosby–Year Book Inc; 1995.
20. Burget GC. Surgical restoration of the nose. In: Mansor M, Marsh JL, eds. *Current Therapy in Plastic and Reconstructive Surgery.* Phildelphia, Pa: BC Decker; 1989:400-412.
21. Alford EL, Baker SR, Shumrick KA. Midforehead flaps. In: Hurley R, ed. *Local Flaps in Facial Reconstruction.* St Louis, Mo: Mosby–Year Book Inc; 1995: 197-223.
22. Burget GC, Menick FJ. The subunit principle in nasal reconstruction. *Plast Reconstr Surg.* 1985;76:239-247.
23. Gonzalez-Ulloa M, Castillo A, Stevens E, Fuertes GA, Leonelli F, Ubaldo F. Preliminary study of the total restoration of the facial skin. *Plast Reconstr Surg.* 1954; 13:151-161.
24. Baker SR. Regional flaps in facial reconstruction. *Otolaryngol Clin North Am.* 1990; 23:925-945.
25. Hoffman HT, Baker SR. Nasal reconstruction with the rapidly expanded forehead flap. *Laryngoscope.* 1989;99:1096-1098.

©2000 American Medical Association. All rights reserved.
Downloaded From: http://archderm.jamanetwork.com/ on 05/19/2013