OBSERVATION

# Lichenoid Dermatitis in Paraneoplastic Pemphigus

## *A Pathogenic Trigger of Epitope Spreading?*

*Glen M. Bowen, MD; Neill T. Peters, MD; David P. Fivenson, MD; Lyndon D. Su, MD; Hossein C. Nousari, MD; Grant J. Anhalt, MD; Kevin D. Cooper, MD; Seth R. Stevens, MD*

**Background:** In select cases, lichen planus has been observed to be a paraneoplastic condition sometimes associated with paraneoplastic pemphigus, a disease featuring autoantibodies directed against plakin proteins, desmogleins 3 and 1, and a still uncharacterized 170-kd antigen. Epitope spreading describes the phenomenon where underlying chronic inflammation leads to the sequential recognition of new epitopes on self-proteins over time.

**Observations:** Five of 6 patients diagnosed as having paraneoplastic pemphigus had concomitant clinical and histological features of lichen planus. In 1 patient, results of the initial indirect immunofluorescence on rat bladder were negative and only 2 of the 5 antigens were identified by immunoprecipitation. After 1 year of worsening disease, repeated testing confirmed the presence of antibodies directed against all 6 of the implicated antigens, supportive of our hypothesis that epitope spreading may occur in paraneoplastic pemphigus.

**Conclusions:** Lichenoid eruptions may predispose to an early evolutionary stage of paraneoplastic pemphigus. Cell-mediated autoimmunity at the dermoepidermal junction may promote the exposure of self-antigens and the development of subsequent and progressive humoral autoimmunity. As such, paraneoplastic pemphigus may demonstrate epitope spreading in a human, humoral-mediated autoimmune disease.

*Arch Dermatol. 2000;136:652-656*

*From the Departments of Dermatology, University of Utah, Salt Lake City (Dr Bowen), Henry Ford Hospital, Detroit, Mich (Dr Fivenson), and University of Michigan, Ann Arbor (Dr Su); Division of Dermatoimmunology, Johns Hopkins Medical Institutions, Baltimore, Md (Drs Nousari and Anhalt); and Departments of Dermatology, Case Western Reserve University, University Hospitals of Cleveland, and the Louis Stokes Veterans Affairs Medical Center, Cleveland, Ohio (Drs Cooper and Stevens). Dr Peters is in private practice in Chicago, Ill.*

FIRST DESCRIBED in 1990, paraneoplastic pemphigus (PNP) is a blistering and erosive mucocutaneous disease associated with an underlying malignant neoplasm, usually of lymphoreticular origin.[1] The disease features anti-epidermal cell surface autoantibodies that are directed against a unique complex of self-proteins. Mucous membrane involvement is usually severe, painful, and refractory to treatment. Cutaneous lesions are polymorphous, including erythema, bullae, erosions, papulosquamous eruptions, and erythema multiforme–like lesions. The prognosis in PNP is very poor, except in cases associated with less aggressive neoplasms, such as thymomas and Castleman disease, that may respond to medical and/or surgical treatment. Otherwise, management options include high-dose prednisone, immunosuppressive therapy, and plasmapheresis. Despite treatment, however, a refractory course culminating in death is typical.

Five diagnostic criteria for PNP have been proposed[1]: (1) a polymorphous mucocutaneous eruption; (2) histopathological findings including epidermal acantholysis, dyskeratosis, and vacuolar interface changes; (3) direct immunofluorescence positive for intercellular IgG and C3 with or without involvement of the basement membrane zone; (4) serum autoantibodies to multiple epithelia; and (5) immunoprecipitation of a unique complex of 4 polypeptides: 250, 230, 210, and 190 kd, with a fifth protein subsequently added, a 170-kd putative transmembrane glycoprotein.[2] New evidence has shown that antibodies directed against a 500-kd plakin, HD1/plectin, are commonly present in PNP but not detected with standard immunoprecipitation methods.[3]

*For editorial comment see page 663*

In the past 8 years, 6 patients have been diagnosed as having PNP at either the University of Michigan Medical Center in Ann Arbor or the Henry Ford Hospital in Detroit, Mich. Remarkably, 5 of the 6 patients had clinical and histological evi-



©2000 American Medical Association. All rights reserved.
Downloaded From: http://archderm.jamanetwork.com/ on 05/22/2013

**Patients With Paraneoplastic Pemphigus and Concomitant Lichen Planus–Like Skin Lesions***

| Patient No./ Sex/Age, y | Skin Findings | Histological Findings | Rat Bladder IIF/ Immunoprecipitation | Malignant Neoplasm | Outcome |
|---|---|---|---|---|---|
| 1/F/63 | Oral lesions, lichenoid papules and vesicles on chest, back, and arms | Bullous lichen planus | +RB/all present (250, 230, 210, 190, 170 kd) | CLL, remission for 6 y | Death (sepsis) |
| 2/F/46 | Oral and vulvar erosions, lichenoid papules on trunk and extremities | Lichen planus | +RB/all present | Castleman tumor at autopsy | Death (bronchiolitis obliterans) |
| 3/M/56 | Oral erosions, lichenoid papules on trunk, groin, and extremities | Lichen planus | +RB/not completed because of laboratory difficulties | CLL for 4 y | Death (sepsis) |
| 4/M/51 | Oral and genital erosions, lichenoid papules on trunk and extremities | Bullous lichen planus | –RB/all present except absent 190 kd | Non-Hodgkin lymphoma, follicular center cell type at autopsy | Death (sepsis, respiratory failure) |
| 5/F/74 | Oral erosions, lichenoid papules and plaques on trunk and extremities | Lichen planus | Initial: –RB/170, weak 250 kd, absent 230, 210, 190 kd; 1 y later: +RB/all present | Intraductal breast carcinoma (3 mo before death) | Death (respiratory failure) |

*IIF indicates indirect immunofluorescence; CLL, chronic lymphocytic leukemia; plus sign, test was positive; and minus sign, test was negative.

dence of a coexisting dermatitis consistent with lichen planus. In some cases the lichen planus preceded the diagnosis of PNP by years, and in others it appeared concomitantly with PNP (**Table**). One case was particularly peculiar; the patient had a remote history of lichen planus and then had an apparent recurrence years later with severe oral involvement. Immunofluorescence testing results led to suspicion of PNP, yet diagnostic criteria were lacking, only to become satisfied 1 year later after a second test. This case led us to hypothesize that chronic inflammation of the dermoepidermal junction (in a lichen planus–like pattern) may have ultimately exposed cellular adhesion antigens, prompting a subsequent humoral immune response characteristic of PNP. This case is presented herein.

## REPORT OF A CASE

A 74-year-old white woman with a remote history of self-limited lichen planus went to her local physician because of painful oral erosions. Subsequently, she developed a violaceous papular eruption on the trunk and extremities clinically and histologically consistent with lichen planus. A skin biopsy specimen disclosed a band-like interface dermatitis of monomorphous lymphocytes with squamatization of the basal layer and subepidermal clefts and multiple necrotic keratinocytes consistent with lichen planus (**Figure 1** and **Figure 2**). Treatment with intramuscular triamcinolone diacetate injections weekly for 6 weeks was ineffective, and worsening of the oral erosions and intractable pain led to admission to her community hospital for 10 days of intravenous prednisolone, tapering to oral prednisone, but with minimal improvement.

The patient was referred to the University of Michigan and demonstrated conjunctival injection and extensive oral and gingival ulcerations with pseudomembrane formation on the tongue and buccal mucosae. Vermilion border involvement was present. The skin had an extensive reticulate erythema with numerous violaceous lichenoid papules and rare intact bullae over the torso and extremities (**Figure 3** and **Figure 4**). Direct and indirect immunofluorescent studies demonstrated IgG and IgM deposition in an intercellular epidermal cell surface pattern as well as linear C3 and fibrin along the basement membrane zone, raising the suspicion of PNP. However, an indirect study of the patient's serum against rat bladder transitional epithelium was negative. Immunoprecipitation showed a clear band coinciding with the 170-kd antigen and an equivocal band at 250 kd (desmoplakin I). Although there were faint bands corresponding to the 230-, 210-, and 190-kd positions (bullous pemphigoid antigen, desmoplakin II/envoplakin, and periplakin, respectively), the weak intensity mirrored the negative control and these bands were interpreted as negative (**Figure 5**, left).

Despite the equivocal immunoprecipitation and rat bladder test results, PNP was still suspected because of the recalcitrance and severity of the oral disease coupled with the combined pemphigoid-pemphigus pattern on direct and indirect immunofluorescence. A rigorous search for an underlying neoplasm was undertaken, which included a mammogram, pelvic examination with Papanicolaou smear, colonoscopy, and computed tomographic scans of the chest, abdomen, and pelvis, but all results were negative or normal.

Therapy was initiated with prednisone (1 mg/kg) and azathioprine (150 mg/d), but this was ineffective. The patient was then placed on a regimen including prednisone, cyclosporine (3 mg/kg per day), and hydroxychloroquine (200 mg twice daily), which resulted in dramatic improvement of the diffusely distributed reticulate erythema and lichenoid papules on the body, but no improvement of the oral ulcerations.

After 1 year, progressive disease prompted us to repeat the immunoprecipitation and immunofluorescent studies, and samples were submitted to the same laboratories where initial testing had been performed. Interestingly, both test results were now unequivocally positive. On immunoprecipitation, the entire complex of



©2000 American Medical Association. All rights reserved.
Downloaded From: http://archderm.jamanetwork.com/ on 05/22/2013

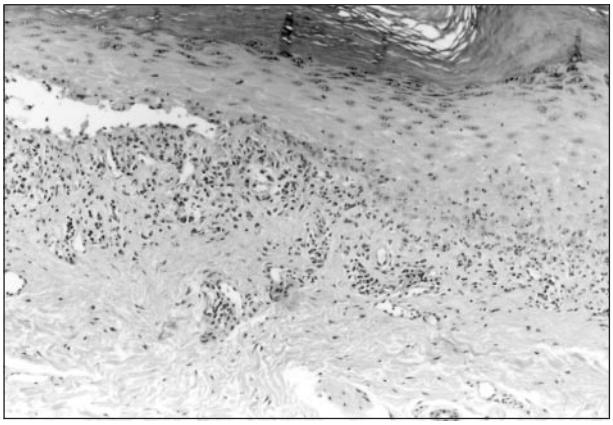

**Figure 1.** *Low-power magnification of a lichenoid interface dermatitis with necrotic keratinocytes and a subepidermal cleft (hematoxylin-eosin, original magnification ×150).*

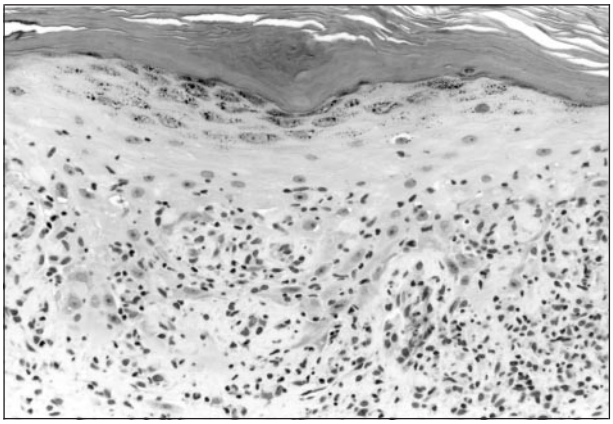

**Figure 2.** *High-power magnification of the lichenoid interface dermatitis (hematoxylin-eosin, original magnification ×400).*

**Figure 3.** *Lavender papules coalescing into plaques on the trunk, histologically consistent with lichen planus.*

antibodies typical of the PNP was easily identified: desmoplakin I (250 kd), bullous pemphigoid antigen 1 (230 kd), the desmoplakin II/envoplakin doublet (210 kd), periplakin (190 kd), and the still unidentified 170-kd antigen (Figure 5, right). Additionally, the patient's serum now reacted strongly with rat bladder epithelium on indirect immunofluorescence, and the diagnosis of PNP was finally confirmed.

**Figure 4.** *Close-up of lavender flat-topped papules coalescing into plaques.*

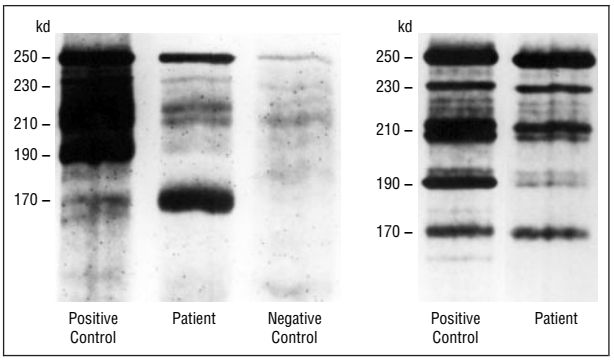


**Figure 5.** *Left, Initial immunoprecipitation with bands at 250 and 170 kd (with positive and negative controls). Right, Follow-up immunoprecipitation at 1 year with bands at 250, 230, 210, weak 190, and 170 kd (with a positive control).*

Evaluation to identify an underlying malignant neoplasm was reinitiated, and an abnormal mammogram (which had been unremarkable 1 year earlier) led to the diagnosis of an intraductal carcinoma of the breast. This was somewhat surprising, since most malignant neoplasms associated with PNP are lymphoreticular. Failing to respond to treatment for breast cancer, the patient ultimately died of respiratory failure 18 months after presenting with what was initially thought to be a recurrence of lichen planus with oral involvement. An autopsy was not performed, but the respiratory failure was thought most likely caused by bronchiolitis obliterans, a frequent complication of PNP.

## COMMENT

The observation of 5 consecutive patients clinically diagnosed as having lichen planus who ultimately proved to have PNP is striking. Although our group[4] and others[5-10] have observed PNP manifesting as lichenoid eruptions, this case series suggests that such a presentation may be more common than previously recognized.[11]

A few conclusions can be derived from our observations. First, it is apparent that the presence of antibodies against the 250- and 170-kd antigens is sufficient to give the clinical expression of PNP. It has previously been concluded that not all 5 polypeptides are required for disease expression; the 170-kd poly-



©2000 American Medical Association. All rights reserved.
Downloaded From: http://archderm.jamanetwork.com/ on 05/22/2013

peptide was the most commonly found protein in PNP in one study[2] and can occur in various combinations with the other 4 polypeptides.[12]

Second, this case also demonstrates the phenomenon of epitope spreading, defined as the initial recognition of an epitope by a single autoantibody followed by the generation of other antibodies directed against related epitopes on the same protein or other epitopes in the same tissue.[13] Lichen planus has been previously described as a potential paraneoplastic process in select patients.[14] These 5 cases of PNP demonstrate that lichenoid eruptions can precede or follow the signs or symptoms of the underlying malignant neoplasm. Two compelling possibilities exist: (1) a preexisting and chronic lichenoid reaction pattern in the skin may predispose some patients with cancer to developing humoral autoimmunity to components of the basement membrane, and/or (2) an underlying neoplasm may spur the development of a cell-mediated lichenoid interface dermatitis; otherwise concealed basement membrane epitopes then become exposed and thus vulnerable to recognition by autoreactive T cells, ultimately leading to B-cell activation and autoantibody production.

The hypothesis that an inflammatory process directed against the basement membrane results in tissue damage that can predispose toward the development of humoral-mediated bullous disease was cogently stated and reviewed by Chan et al.[13] They pointed to several case series in which an inflammatory cutaneous or noncutaneous disease was followed by the development of an antibody-mediated blistering disease: lichen planus pemphigoides,[15] psoriasis,[16,17] chronic cutaneous lupus,[18] and ulcerative colitis.[19,20] In addition, ocular cicatricial pemphigoid occurring as a sequela to Stevens-Johnson syndrome[21] and linear IgA disease developing after long-standing ulcerative colitis[22,23] have also been reported.

The phenomenon of antigenic diversification or epitope spreading occurs in both cell-mediated and antibody-mediated autoimmune diseases, including experimental allergic encephalitis[24] and a lupuslike disease in mice[25] and in multiple sclerosis in humans.[26] In their experiments with mice prone to contracting a lupuslike disease, Fatenejad et al[25] described a reproducible hierarchy of antibody development over time. They postulated that similar antibody diversification in humans with systemic lupus erythematosus may occur, since antibodies to multiple epitopes of small nuclear ribonucleoprotein particles in the serum samples of patients with systemic lupus erythematosus have been observed.

The sequential development of autoantibody arrays has been well documented in mice but has proved more difficult to detect in humans. The clinician, after all, is not likely to screen for autoantibodies in patients until clinical signs and symptoms of a disease are well manifest, a time when the full array of the autoantibodies is already established. However, there is one report in the literature in which a patient with pemphigus vulgaris presented with clinical disease restricted to mucosal surfaces and expressed autoantibodies to desmoglein 3.[27] Later, when the patient developed skin disease in addition to the mucosal inflammation, newly arisen autoantibodies to desmoglein 1 were detected. To our knowledge, the case presented in our report is the second clear demonstration of the sequential development of pathogenic antibodies to distinct proteins in a humorally mediated disease in humans.

If epitope spreading represents a common pathogenic mechanism and not just an idiosyncrasy of a few isolated cases, detection of antibody diversification should be reproducible. From our experience, severe and unresponsive oral lichen planus is worrisome indeed, and, in addition to screening for the well-documented association with occult hepatitis C infection,[28,29] a look into the possibility of PNP seems warranted. In such cases we have learned to perform screening direct and indirect immunofluorescence studies. When features of both pemphigus and pemphigoid exist, indirect immunofluorescence with rat bladder and immunoprecipitation studies are indicated. Acting on early clinical suspicions should capture future cases of evolving PNP where epitope spreading is occurring. The challenge remains to better define the prevalence and characteristics of lichenoid dermatitis in these patients and further investigate the potential role of cell-mediated immunity at the dermoepidermal junction as a potential participant in the pathogenesis of this disease.

*Accepted for publication September 16, 1999.*

*This research was supported in part by grants 1-K08AR02063-01 and P-30AR-39750 from the National Institutes of Health, Bethesda, Md; Veterans Affairs Medical Research Service, Washington, DC; and the Dermatology Foundation Career Development Award, Evanston, Ill (Dr Stevens).*

*Corresponding author: Glen M. Bowen, MD, Department of Dermatology, 50 N Medical Dr, University of Utah School of Medicine, Salt Lake City, UT 84132 (e-mail: gbowen@derm.med.utah.edu).*

## REFERENCES

1. Anhalt GJ, Kim SC, Stanley JR, et al. Paraneoplastic pemphigus: an autoimmune mucocutaneous disease associated with neoplasia. *N Engl J Med.* 1990; 323:1729-1735.
2. Anhalt GJ, Josiane H, Takahara K, et al. Identification of a putative transmembrane antigen in paraneoplastic pemphigus [abstract]. *J Invest Dermatol.* 1993; 100:508.
3. Proby C, Fujii Y, Owaribe K, Nishikawa T, Amagai M. Human autoantibodies against HD1/plectin in paraneoplastic pemphigus. *J Invest Dermatol.* 1999;112: 153-156.
4. Stevens SR, Griffiths CE, Anhalt GJ, Cooper KD. Paraneoplastic pemphigus presenting as a lichen planus pemphigoides-like eruption. *Arch Dermatol.* 1993; 129:866-869.
5. Camisa C, Helm TN, Liu YC, et al. Paraneoplastic pemphigus: a report of three cases including one long-term survivor. *J Am Acad Dermatol.* 1992;27:547-553.
6. Jansen T, Plewig G, Anhalt GJ. Paraneoplastic pemphigus with clinical features of erosive lichen planus associated with Castleman's tumor. *Dermatology.* 1995; 190:245-250.
7. Lotem M, Ingber A, Sandbank M, Hazaz B. Lichen planus pemphigoides with features of lichen planus and pemphigus vulgaris. *Arch Dermatol.* 1989;125: 707-708.
8. Krunic AL, Kokai D, Bacetic B, et al. Retroperitoneal round-cell liposarcoma associated with paraneoplastic pemphigus presenting as lichen planus pemphigoides-like eruption. *Int J Dermatol.* 1997;36:526-529.
9. Mahler V, Antoni C, Anhalt GJ, et al. Graft-versus-host–like mucocutaneous erup-



©2000 American Medical Association. All rights reserved.
Downloaded From: http://archderm.jamanetwork.com/ on 05/22/2013

tions with serological features of paraneoplastic pemphigus and systemic lupus erythematosus in a patient with non-Hodgkin's lymphoma. *Dermatology*. 1998; 197:78-83.
10. Beylot-Barry M, Doutre MS, Vergier B, et al. Lichenoid paraneoplastic pemphigus in low-grade nodular lymphoma [in French]. *Ann Dermatol Venereol*. 1998; 125:720-723.
11. Horn TD, Anhalt GJ. Histologic features of paraneoplastic pemphigus. *Arch Dermatol*. 1992;128:1091-1095.
12. Hashimoto T, Amagai M, Watanabe K, et al. Characterization of paraneoplastic pemphigus autoantigens by immunoblot analysis. *J Invest Dermatol*. 1995;104: 829-834.
13. Chan LS, Vanderlugt CJ, Hashimoto T, et al. Epitope spreading: lessons from autoimmune skin diseases. *J Invest Dermatol*. 1998;110:103-109.
14. Helm TN, Camisa C, Liu AY, Valenzuela R, Bergfeld WF. Lichen planus associated with neoplasia: a cell-mediated immune response to tumor antigens? *J Am Acad Dermatol*. 1994;30:219-224.
15. Davis AL, Bhogal BS, Whitehead P, et al. Lichen planus pemphigoides: its relationship to bullous pemphigoid. *Br J Dermatol*. 1991;125:263-271.
16. Grattan CE. Evidence of an association between bullous pemphigoid and psoriasis. *Br J Dermatol*. 1985;113:281-283.
17. Kirtschig G, Chow ET, Venning VA, Wojnarowska FT. Acquired subepidermal bullous diseases associated with psoriasis: a clinical, immunopathological and immunogenetic study. *Br J Dermatol*. 1996;135:738-745.
18. Ishikawa O, Zaw KK, Miyachi Y, Hashimoto T, Tanaka T. The presence of anti-basement membrane zone antibodies in the sera of patients with non-bullous lupus erythematosus. *Br J Dermatol*. 1997;136:222-226.
19. Barth JH, Kelly SE, Wojnarowska F, et al. Pemphigoid and ulcerative colitis. *J Am Acad Dermatol*. 1988;19:303-308.
20. Harrison PV, Blewitt RW, Allen J, et al. Bullous pemphigoid and ulcerative colitis: a report of two cases and description of immunoblot findings. *Br J Dermatol*. 1996;134:599-600.
21. Chan LS, Soong HK, Foster CS, Hammerberg C, Cooper KD. Ocular cicatricial pemphigoid occurring as a sequela of Stevens-Johnson syndrome. *JAMA*. 1991; 266:1543-1546.
22. Smith EP, Zone JJ. Linear IgA bullous dermatosis. In: Arndt KA, LeBoit PE, Robinson JK, Wintroub BU, eds. *Cutaneous Medicine and Surgery*. Philadelphia, Pa: WB Saunders Co; 1996:698-703.
23. Paige DG, Leonard JN, Wojnarowska F, Fry L. Linear IgA disease and ulcerative colitis. *Br J Dermatol*. 1997;136:779-782.
24. Lehmann PV, Sercarz EE, Forsthuber T, Dayan CM, Gammon G. Determinant spreading and the dynamics of the autoimmune T-cell repertoire. *Immunol Today*. 1993;14:203-208.
25. Fatenejad S, Mamula MJ, Craft J. Role of intermolecular/intrastructural B- and T-cell determinants in the diversification of autoantibodies to ribonucleoprotein particles. *Proc Natl Acad Sci U S A*. 1993;90:12010-12014.
26. Tuohy VK, Fritz RB, Ben-Nun A. Self-determinants in autoimmune demyelinating disease: changes in T-cell response specificity. *Curr Opin Immunol*. 1994; 6:887-891.
27. Ding X, Aoki V, Mascaro JM Jr, Lopez-Swiderski A, Diaz LA, Fairley JA. Mucosal and mucocutaneous (generalized) pemphigus vulgaris show distinct autoantibody profiles. *J Invest Dermatol*. 1997;109:592-596.
28. Sanchez-Perez J, De Castro M, Buezo GF, Fernandez-Herrera J, Borque MJ, Garcia-Diez A. Lichen planus and hepatitis C virus: prevalence and clinical presentation of patients with lichen planus and hepatitis C virus infection. *Br J Dermatol*. 1996; 134:715-719.
29. Mignogna MD, Lo Muzio L, Favia G, Mignogna RE, Carbone R, Bucci E. Oral lichen planus and HCV infection: a clinical evaluation of 263 cases. *Int J Dermatol*. 1998;37:575-578.



©2000 American Medical Association. All rights reserved.
Downloaded From: http://archderm.jamanetwork.com/ on 05/22/2013