OBSERVATION

Phacomatosis Pigmentokeratotica

Report of New Cases and Further Delineation of the Syndrome

Gianluca Tadini, MD; Lucia Restano, MD; Ricardo Gonzáles-Pérez, MD; M. Antonia Gonzáles-Enseñat, MD; M. Asunción Vincente-Villa, MD; Stefano Cambiaghi, MD; Paolo Marchettini, MD; Massimo Mastrangelo, MD; Rudolf Happle, MD

Background: The epidermal nevus syndromes include different diseases that have the common feature of mosaicism. One of these has been recently identified and named *phacomatosis pigmentokeratotica,* in analogy to phacomatosis pigmentovascularis. It is characterized by an organoid nevus with sebaceous differentiation, a speckled-lentiginous nevus, and other associated anomalies. It has been hypothesized that this syndrome is caused by a particular genetic mechanism known as the twin-spot phenomenon.

Observations: We describe 3 patients manifesting an association of organoid nevus showing sebaceous differentiation and speckled-lentiginous nevus with associated anomalies and update the neurologic findings of a previously described patient. Hemiatrophy seems to be a common finding in all cases; hyperpathia, dysesthesia, and hyperhidrosis, as well as other neurologic defects, may be present.

Conclusions: The findings in these patients allowed us to better delineate this syndrome. Further studies are needed to elucidate the underlying genetic defect. At present, however, the hypothesis that best explains this phenotype is twin spotting. Clinical recognition of this syndrome can contribute to the classification of the epidermal nevus syndromes and give insight into unusual genetic mechanisms occurring in humans.

Arch Dermatol. 1998;134:333-337

From the Center of Cutaneous Inherited Diseases, Institute of Dermatological Science, Istituto di Ricovero e Cura a Carattere Scientifico Policlinico, (Drs Tadini, Restano, and Cambiaghi); the Department of Neurology, S Raffaele Hospital, (Dr Marchettini); and the Department of Neurophysiopathology, Institui Clinici di Perfezionamento (Dr Mastrangelo), Milan, Italy; the Department of Dermatology, Hospital de Cruces, Bilbao (Dr Gonzáles-Pérez) and the Department of Dermatology, Hospital Sant Joan de Déu, Barcelona (Drs Gonzáles-Enseñat and Vincente-Villa), Spain; and the Department of Dermatology, University of Marburg, Marburg, Germany (Dr Happle).

THE EPIDERMAL nevus syndromes include different diseases that have the common feature of mosaicism. The association of speckled-lentiginous nevus (SLN), organoid nevus (ON) with sebaceous differentiation and skeletal and neurologic anomalies constitutes a specific syndrome that has been called *phacomatosis pigmentokeratotica,* in analogy to phacomatosis pigmentovascularis. Phacomatosis pigmentokeratotica should be differentiated from other epidermal nevus syndromes. It has been hypothesized that the co-occurrence of the 2 different nevi reflects a twin-spot phenomenon. We describe 3 patients affected with phacomatosis pigmentokeratotica. In addition, we update the neurologic findings for a case reported by Tadini et al[1] and further delineate the features of this syndrome.

PATIENT REPORTS

PATIENT 1

A 32-year-old man, born at term from an uncomplicated pregnancy to nonconsanguineous parents, had an unremarkable family history. An SLN manifested in a mosaic checkerboard pattern[2] predominantly involving the left side of the body and a linear ON on the scalp, neck, and upper back on the right side, stopping at the midline and intermingling on the left side with the SLN (**Figure 1** and **Figure 2**). The ON was first noted at 6 months of age, whereas the SLN was noted at 18 months of age. Excision of some pigmented lesions of the SLN showed classic melanocytic nevi; some specimens also showed hyperpigmentation of the basal cell layer. In 1990, a malignant melanoma, level II, was excised from the SLN located in the lumbar area; to date, there is no evidence of metastatic growth. A biopsy specimen from the occipital region showed an organoid nevus of Jadassohn with sebaceous and apocrine hyperplasia. The karyotype was normal (46, XY). In addition, the patient had dextroconvex scoliosis of the dorsolumbar column that had been present since childhood and had worsened with time. The left leg was 2 cm shorter than the right leg.

A neurologic examination showed hemiatrophy and mild strength reduction

©1998 American Medical Association. All rights reserved.
Downloaded From: http://archderm.jamanetwork.com/ on 05/22/2013

Figure 1. *Patient 1. Speckled-lentiginous nevus showing a checkerboard distribution and hemiatrophy with postural deviation.*

Figure 2. *Patient 1. Linear arrangement of the organoid nevus (ON) involving the neck and part of the upper back. The ON intermingles with the speckled-lentiginous nevus and stops sharply at the midline.*

of the left arm and leg, with hyperreflexia of the ankle and knee joints. A severe and disabling hyperpathia (ie, abnormally painful reaction to stimuli), as well as a decreased pain threshold, involved the trunk and arm on the left side of the body and was more pronounced on the anterior aspect. Moreover, the left side of the trunk showed hyperhidrosis (**Figure 3**), which was more severe on the anterior aspect and stopped at the upper scapular border, involving the axilla and the proximal part of the left arm and hand, but sparing the forearm. These neurologic anomalies developed slowly and worsened during adolescence. Higher cortical functions and cranial nerves, as well as sensory functions, were normal. There were no abnormalities with the upright position and movement coordination. Osteotendinous and postural reflexes, those of vibratory sensitivity, deep sensitivity, and coordination, seemed unimpaired. The results of magnetic resonance imaging of the skull and medulla were unremarkable. The patient denied permission for telethermography and testing of the autonomic functions (as performed in patient 4).

PATIENT 2

A 16-year-old girl, born to nonconsanguineous parents after a normal pregnancy, had an unremarkable family history. She had an epidermal nevus on the left side of the body following the lines of Blaschko and a checkerboard

Figure 3. *Patient 1. Close-up view of the speckled-lentiginous nevus. Note the advanced scoliosis. Sweat drops due to hyperhidrosis are visible in the left lumbar region.*

Figure 4. *Patient 2 at 6 years of age. Systematized epidermal nevus involving the left side of the body.*

SLN involving the lumbar area, without a sharp midline separation (**Figure 4** and **Figure 5**). The epidermal nevus had been present since her birth; the SLN became manifest during her first 2 years of life. A biopsy specimen obtained from a café au lait area of the SLN without melanocytic nevi showed features similar to lentigo simplex, and a biopsy from a dark papule revealed a dermal melanocytic nevus. A biopsy specimen obtained from the linear nevus showed acanthosis and papillomatosis compatible with an epidermal nevus, without sebaceous or other organoid differentiation. The girl was blind in her right eye because of a congenital glaucoma. At 6 years of age, she had been examined by an orthopedic surgeon who reported findings of congenital torticollis, left facial hemiatrophy, and dextroconvex scoliosis of the dorsolumbar column. In addition, her right leg was 0.5 cm shorter than the left. A neurologic examination, performed when the girl was 3 years old, detected no abnormalities. At present, the girl shows a mild intellectual deficit.

©1998 American Medical Association. All rights reserved.
Downloaded From: http://archderm.jamanetwork.com/ on 05/22/2013

PATIENT 3

A 5-year-old boy, the first child of healthy nonconsanguineous parents, was born preterm (at the 33rd week) with hydrops fetalis. An ON manifested in a unilateral arrangement from head to foot on the left side. Psychomotor retardation was present but resolved partially with time. At 2 years of age, a checkerboard SLN appeared on the side of the ON, involving the face, trunk, and arm. At 4 years of age, a number of pink-tan, round papules appeared on the SLN of the frontal region. Clinically, these lesions resembled Spitz nevi. The parents refused permission for a histopathological examination of the cutaneous lesions.

Since birth, the boy had been affected with severe conductive hypacusis at the brainstem level. He had mild eye abnormalities (ie, large vessel abnormalities, with common tracts of temporal–superior nasal and nasal–temporal inferior) with esotropia. Facial dysmorphism was present.

At 2 years of age, hypophosphatemic rickets was noted, which resulted in multiple fractures and a severe delay in physical development. The results of magnetic resonance imaging of the skull, an electroencephalogram, and renal echography were normal. A total body radiogram showed multiple fractures. The karyotype was normal.

PATIENT 4

A 13-year-old girl, born to nonconsanguineous parents, had an unremarkable family history. At the time of the previous report of this case,[1] the neurologic findings were unclear and were not described in detail; the report was limited to the dermatological findings. These consisted of an ON in a linear distribution with multiple streaks on the right side of her body and an SLN in a checkerboard pattern, predominantly on the left side of her body. Both diagnoses were confirmed histopathologically. Some small, flat, angiomatous lesions were present on the right side of her body. A diffuse ichthyosislike hyperkeratosis was also present. Later it became clear that the patient also had hemiatrophy of the right arm and leg and scoliosis, similar to that observed in patient 1. The neurologic examination showed hyperpathia to mechanical stimuli, dysesthesia to warm and cold stimuli, and hyperhidrosis on the right hemibody below the face, particularly on the arm. The higher mental functions were normal. The karyotype was normal (46, XX).

The sensory examination revealed normal spontaneous sensation. The patient complained of abnormal evoked sensations on the right side of her body that spared the face. The following findings were present: normal perception threshold for static (von Frey, 2.36 and symmetrical on both sides of the body) and dynamic mechanical stimuli. The pain threshold to mechanical static stimuli was reduced on the right side (von Frey, 5.46) compared with the left side (von Frey, 5.89) of the body. The estimated pain magnitude and duration were greater on the right side of the body. Cold and warm stimuli evoked an "unpleasant but not painful" sensation on the right arm, particularly on the right hand. Quantitative sensory testing (TSA 2000 Medoc Israel) for warm, cold, and pain to hot and cold stimuli documented a symmetrical and normal perception threshold in all areas. Total body telethermography showed asymmetry of the thermal profile with a colder right hemibody; the highest asymmetry (2.3°C) was found on the back of the hand. Galvanic skin resistance showed increased spontaneous and evoked (acoustic stimuli and electrical stimulation of the median nerve) responses on the right palm and sole. The findings of magnetic resonance imaging were unremarkable.

Figure 5. *Patient 2 at 6 years of age. Speckled-lentiginous nevus in the lumbar area. With time, the number of pigmentary nevi markedly increased.*

COMMENT

The epidermal nevus syndromes include several diseases that differ in genetic origin but share the common feature of mosaicism. Among these phenotypes, the Proteus syndrome, CHILD (congenital hemidysplasia with ichthyosiform erythroderma and limb defects) syndrome, nevus comedonicus syndrome, Becker nevus syndrome, and Schimmelpenning syndrome have been delineated.[3]

The Schimmelpenning syndrome is characterized by the presence of an ON showing sebaceous differentiation in association with ocular, cerebral, and skeletal defects. The range of additional associated cutaneous and extracutaneous abnormalities varies substantially and may cause difficulties in the categorization of this type of syndrome. Although the presence of multiple melanocytic nevi has often been described in this condition, we believe that the pigmentary lesions observed in the present patients cannot be categorized as a feature of Schimmelpenning syndrome.

By contrast, the observation of a series of patients manifesting an ON that usually shows sebaceous differentiation arranged in a systematic linear pattern and a SLN distributed in a checkerboard pattern, as well as char-

©1998 American Medical Association. All rights reserved.
Downloaded From: http://archderm.jamanetwork.com/ on 05/22/2013

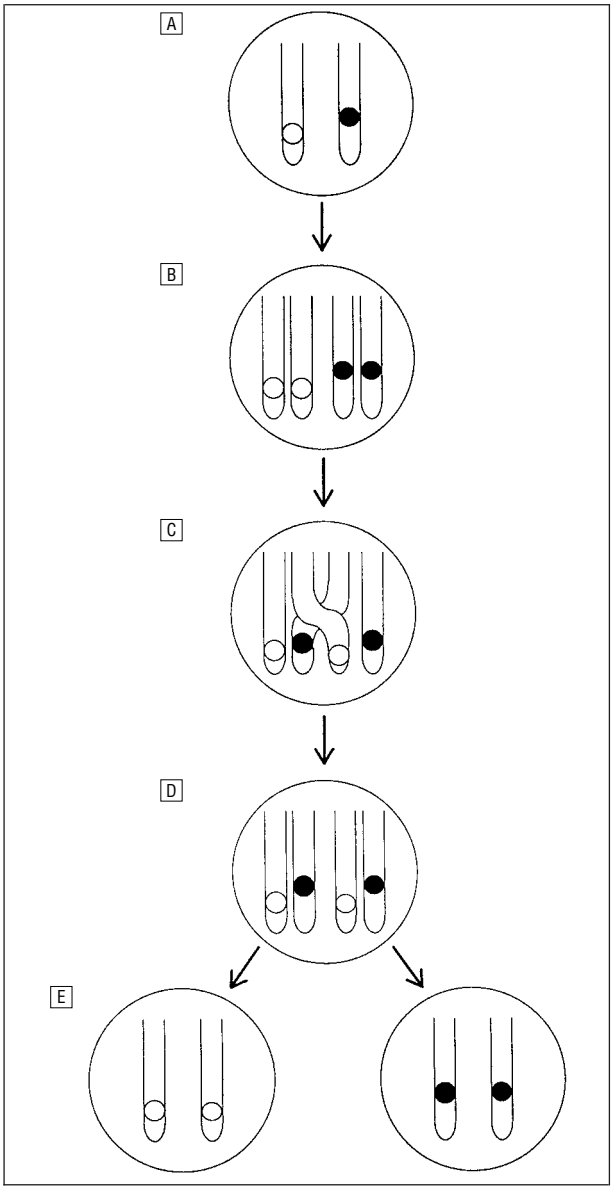

Figure 6. *Mechanism of somatic crossing-over in which 2 homozygous stem cells result in twin spotting. A, Homologous single DNA strands carrying a mutation at either of 2 different loci. B, Semiconservative replication. C, Crossing-over with exchange of the region carrying the 2 mutations. D, Homologous chromosomes, each composed of 2 different chromatids. E, At mitosis, the random arrangement of chromatids may result in 2 different homozygous daughter cells.*

acteristic extracutaneous defects, led us to the conclusion that this condition may represent a distinct syndrome for which we have proposed the term *phacomatosis pigmentokeratotica*.[4] This name was chosen in analogy to phacomatosis pigmentovascularis[5,6] and was first applied to a series of 8 cases reported in the literature; 1 of those cases is patient 4 in the present series.[1] These cases have been given various names, such as epidermal nevus syndrome, sebaceous nevus syndrome, Feuerstein-Mims neuroectodermal syndrome, and "nevus on a nevus."[7-12] In patient 2, a biopsy specimen obtained from the epidermal nevus showed no signs of adnexal hyperplasia. We are unable to say, however, whether such organoid differentiation is absent in all parts of the epidermal nevus.

The hypothesis of 2 independent mutations (due, for instance, to an increased mutability or chromosomal instability) causing this phenotype seems unlikely, because the constant and clearly segmental pattern of the nevi, mostly involving adjacent areas or corresponding regions on either side of the body, differs from the random pattern that would be expected in 2 independent mutations. Therefore, we inferred a common origin from an early postzygotic mutational event resulting in a twin-spot phenomenon. Twin spotting has been extensively studied in plants, as well as in *Drosophila melanogaster,*[13,14] and its occurrence has also been suggested in human skin.[15] It involves the occurrence of 2 different mutant patches involving 2 adjacent or corresponding areas of the body. In a doubly heterozygous embryo, postzygotic crossing-over may result in 2 different homozygous populations of cells constituting the stem cells of the 2 different mutant patches (**Figure 6**). In a similar way, a patient affected with phacomatosis pigmentokeratotica would be heterozygous for 2 different recessive mutations localized in the same chromosome. At an early stage of embryogenesis, a postzygotic recombination would result in 2 homozygous daughter cells representing stem cells of the 2 types of nevi and of the extracutaneous defects distributed in a mosaic pattern.

The 2 nevi need not be contiguous to represent twin spotting. The different cellular lines derived from a common event may migrate in different body segments during embryonic development. However, either lesion follows its usual pattern, ie, the ON, a linear pattern, and the SLN, a checkerboard pattern.

The additional cases we report give us the opportunity to delineate further this new syndrome and to give the following working definition of phacomatosis pigmentokeratotica:

- organoid nevus with sebaceous differentiation, arranged according to Blaschko lines;
- SLN arranged in a checkerboard pattern;
- hemiatrophy with muscular weakness of varying degrees;
- other neurologic defects (eg, segmental dysesthesia, hyperhidrosis, mild mental retardation, seizures, deafness, ptosis, and strabismus).

For the extracutaneous findings, the most consistent anomaly was hemiatrophy. Two of the 5 patients in the present series had striking dysesthesia and hyperhidrosis in a segmental pattern partially corresponding to the distribution of the ON. These findings are apparently characteristic features of this new epidermal nevus syndrome and may contribute further to our understanding of cutaneous embryogenesis and mosaicism.

Patient 3, with an ON and an SLN (in which Spitz nevi arise) in association with hypophosphatemic rickets, is somehow different from the other patients in the present series. Cases of an association between sebaceous nevus, multiple melanocytic nevi, and vitamin D–resistant rickets have been reported.[16-18] Whether these cases represent a variant of phacomatosis pigmentokeratotica or a distinct syndrome remains unclear.

©1998 American Medical Association. All rights reserved.
Downloaded From: http://archderm.jamanetwork.com/ on 05/22/2013

PHACOMATOSIS PIGMENTOKERATOTICA VS SCHIMMELPENNING SYNDROME

The most important differential diagnosis is Schimmelpenning syndrome, a disorder that is likewise characterized by an ON with sebaceous differentiation. In phacomatosis pigmentokeratotica, however, the other typical findings of Schimmelpenning syndrome, such as coloboma and lipodermoid of the conjunctiva, so far, have been absent. We believe that the consideration of phacomatosis pigmentokeratotica as an entity separate from Schimmelpenning syndrome seems reasonable.

PHACOMATOSIS PIGMENTOKERATOTICA VS PHACOMATOSIS PIGMENTOVASCULARIS

These 2 phenotypes can be differentiated easily. However, the similarity of the 2 names may reflect a common genetic mechanism explaining the 2 different disorders, because in 1989, phacomatosis pigmentovascularis was explained as a possible example of twin spotting.[19,20]

CONCLUSION

The recognition of phacomatosis pigmentokeratotica as a separate syndrome may help further establish a reasonable classification of the various epidermal nevus syndromes and facilitate understanding of the mechanisms of mosaicism and twin spotting in human skin. We emphasize that in our patients, the onset of hemiatrophy and hyperhidrosis with dysesthesia was slow and was overlooked during the initial examination. An appropriate delineation of the clinical spectrum of phacomatosis pigmentokeratotica may help physicians to recognize and categorize these neurologic symptoms. Ongoing follow-up of patients with phacomatosis pigmentokeratotica is important to recognize possible malignant degeneration of an SLN.

Accepted for publication July 30, 1997.

We thank Ramon Grimalt, MD, Barcelona, Spain, for suggestions for the manuscript and Gabriele Scarabelli, MD, Milan, Italy, for the photographs of patient 1.

Reprints: Gianluca Tadini, MD, Institute of Dermatological Science, Istituto di Ricovero e Cura a Carattere Scientifico Policlinico, Via pace 9, Milan, Italy (e-mail: centromce@bbs.infosquare.it).

REFERENCES

1. Tadini G, Ermacora E, Carminati G, et al. Unilateral speckled-lentiginous naevus, contralateral verrucous epidermal naevus, and diffuse ichthyosis-like hyperkeratosis: an unusual example of twin spotting? *Eur J Dermatol.* 1995;5:659-663.
2. Happle R. Mosaicism in human skin: understanding the patterns and mechanisms. *Arch Dermatol.* 1993;129:1460-1470.
3. Happle R. How many epidermal nevus syndromes exist? a clinicogenetic classification. *J Am Acad Dermatol.* 1991;25:550-556.
4. Happle R, Hoffmann R, Restano L, Caputo R, Tadini G: Phacomatosis pigmentokeratotica: a melanocytic-epidermal twin nevus syndrome. *Am J Med Genet.* 1996;65:363-365.
5. Hasegawa Y, Yasuhara M. A variant of phacomatosis pigmentovascularis. *Skin Res (Osaka).* 1979;21:178-186.
6. Ruiz-Maldonado R, Tamayo L, Laterza AM, Brawn G, Lopez A. Phacomatosis pigmentovascularis: a new syndrome? report of four cases. *Pediatr Dermatol.* 1987;4:189-196.
7. Goldberg LH, Collins SAB, Siegel DM. The epidermal nevus syndrome: case report and review. *Pediatr Dermatol.* 1987;4:27-33.
8. Kopf AW, Bart RS. Tumor conference: combined organoid and melanocytic nevus. *J Dermatol Surg Oncol.* 1980;6:28-30.
9. Misago N, Narisawa Y, Nishi T, Kohda H. Association between nevus sebaceus and an unusual type of combined nevus. *J Cutan Pathol.* 1994;21:76-81.
10. Stein KM, Shmunes E, Thew M. Neurofibromatosis presenting as the epidermal nevus syndrome. *Arch Dermatol.* 1972;105:229-232.
11. Wauschkuhn J, Rohde B. Systematisierte Talgdüsen-, Pigment- und epitheliale Naevi mit neurologischer Symptomatik: Feuerstein-Mimsches neuroektodermales Syndrom. *Hautarzt.* 1971;22:10-13.
12. Brufau C, Moran M, Armijo M. Névus sur névus: à propos de 7 observations, trois associées à d'autres dysplasies, et une à un melanome malin invasif. *Ann Dermatol Venereol.* 1986;113:409-418.
13. Graf U, Würgler FE, Katz AJ, et al. Somatic mutation and recombination test in *Drosophila melanogaster. Environ Mutagen.* 1984;6:153-188.
14. Vig BK, Paddock EF. Study on the expression of somatic crossing-over in *Glycine max. Theor Appl Genet.* 1970;40:316-321.
15. Happle R, Koopman R, Mier PD. Hypothesis: vascular twin naevi and somatic recombination in man. *Lancet.* 1990;335:376-378.
16. Sugarman GI, Reed WB. Two unusual neurocutaneous disorders with facial cutaneous signs. *Arch Neurol.* 1969;21:242-247.
17. Aschinberg LC, Solomon LM, Zeis PM, Justice P, Rosenthal IM. Vitamin-D resistant rickets associated with epidermal nevus syndrome: demonstration of a phosphaturic substance in the dermal lesions. *J Pediatr.* 1977;91:56-60.
18. Goldblum JR, Headington JT. Hypophosphatemic rickets and multiple spindle and epithelioid nevi associated with linear nevus sebaceus syndrome. *J Am Acad Dermatol.* 1993;29:109-111.
19. Happle R, Steijlen PM. Phacomatosis pigmentovascularis gedeutet als ein Phänomen der Zwillingsfleken. *Hautarzt.* 1989;40:721-724.
20. Happle R. Allelic somatic mutations may explain vascular twin nevi. *Hum Genet.* 1991;86:321-322.

©1998 American Medical Association. All rights reserved.
Downloaded From: http://archderm.jamanetwork.com/ on 05/22/2013