OBSERVATION

Facial Papules in Frontal Fibrosing Alopecia

Evidence of Vellus Follicle Involvement

Aline Donati, MD; Luciana Molina, MD; Isabella Doche, MD; Neusa S. Valente, MD, PhD; Ricardo Romiti, MD, PhD

Background: Frontal fibrosing alopecia is considered a particular clinical form of lichen planopilaris that primarily involves the scalp hair over the frontal hairline. Concomitant involvement of vellus at different body sites has recently been reported. To our knowledge, this is the first report on the involvement of facial vellus by effects of the inflammatory process. Unlike the usual noninflammatory clinical presentation of vellus involvement over other body areas, facial vellus involvement can lead to surface changes that may be recognized both by patients and dermatologists.

Observations: Four patients with typical clinical features of frontal fibrosing alopecia presented with noninflammatory follicular papules over the face, most often inside the temporal area, and described as "roughness" by the patients. Histologic samples showed lichen planopilaris features involving the facial vellus.

Conclusions: The new concept of frontal fibrosing alopecia as a generalized disease is important for treatment planning and research. Dermatologists must learn to recognize facial surface changes and discuss these with the patients, who may attribute this roughness to aging or hormonal changes associated with menopause. Further studies are needed to determine the prevalence of this involvement in patients with frontal fibrosing alopecia.

Arch Dermatol. 2011;147(12):1424-1427

FRONTAL FIBROSING ALOPECIA (FFA) is considered a particular clinical form of lichen planopilaris (LPP) that primarily involves the scalp hair over the frontal hairline. Eyebrows and eyelashes can be variably affected, and alopecia sometimes develops over the axillary and pubic regions. Concomitant involvement of vellus hairs at different body sites has recently been reported[1-3] and indicates that FFA has a larger pathologic extension.

We report on 4 cases of FFA with concomitant involvement of facial vellus. All patients were evaluated in our hair clinic between September 30, 2010, and February 3, 2011, for "roughening" of facial skin associated with frontal hair loss. Demographics, clinical aspects, and other findings (**Table**), as well as results of histopathologic testing of all cases, are presented.

REPORT OF CASES

CASE 1

A 50-year-old postmenopausal woman presented with frontal hairline recession that had started 3 months before her visit to the clinic; peripilar inflammation had developed in the same region. The patient had well-controlled type 2 diabetes mellitus and a 5-year history of eyebrow loss; she also reported roughening of her facial skin in the past few years (**Figure 1** A and B). Results of a previous scalp biopsy had shown lymphocytic and granulomatous perifolliculitis with eccentric atrophy of follicular epithelia and perifollicular fibrosis, confirming the diagnosis of FFA (**Figure 2**A). To study the facial alterations, a biopsy was performed over the zygomatic area and showed perifollicular lymphocytic infiltrate and fibrosis around a vellus. Direct immunofluorescence (DIF) was not performed.

CASE 2

A 53-year-old black woman had developed recession of her frontal hairline, scalp pruritus, and loss of body hair after menopause, 3 years before evaluation in our clinic. She had noticed no decrease in her eyelashes or eyebrows, but her facial skin had changed during the past 5 years (Figure 1C). Biopsies of both the frontal hairline and preauricular region were performed. Histopathologic testing of the scalp showed perifollicular fibrosis, eccentric atrophy of the

Author Affiliations:
Department of Dermatology, University of São Paulo, São Paulo, Brazil.

©2011 American Medical Association. All rights reserved.
Downloaded From: http://archderm.jamanetwork.com/ on 12/08/2013

Table. Demographic and Clinical Features

Patient No./ Race/Age, y	DM	Time Since Menopause, y	Time Since Onset of Frontal Recession	Time Since Onset of Face Changes, y	Eyebrow Involvement	Body Vellus Involvement
1/White/50	+	1	3 mo	5	+	+
2/Black/53	–	3	3 y	5	–	+
3/Black/46	–	<1	1 y	<1	+	+
4/White/50	–	5	3 y	1	+	+

Abbreviations: DM, diabetes mellitus; +, present; –, absent.

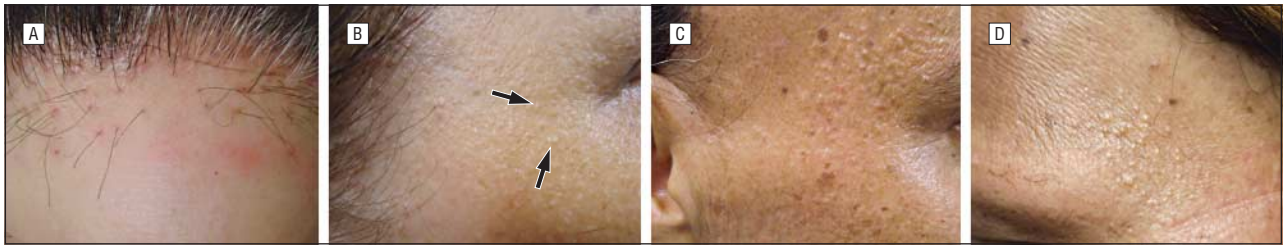

Figure 1. Clinical presentation of frontal fibrosing alopecia. A, Typical inflammatory signs over the frontal hairline of patient 1. B, Follicular papules over the right temporal region of patient 1 (arrows indicate 2 follicular papules). C, Recession of hairline and papules on the right lateral face of patient 2. D, Decreased eyebrows and papules on the left temporal region of patient 3.

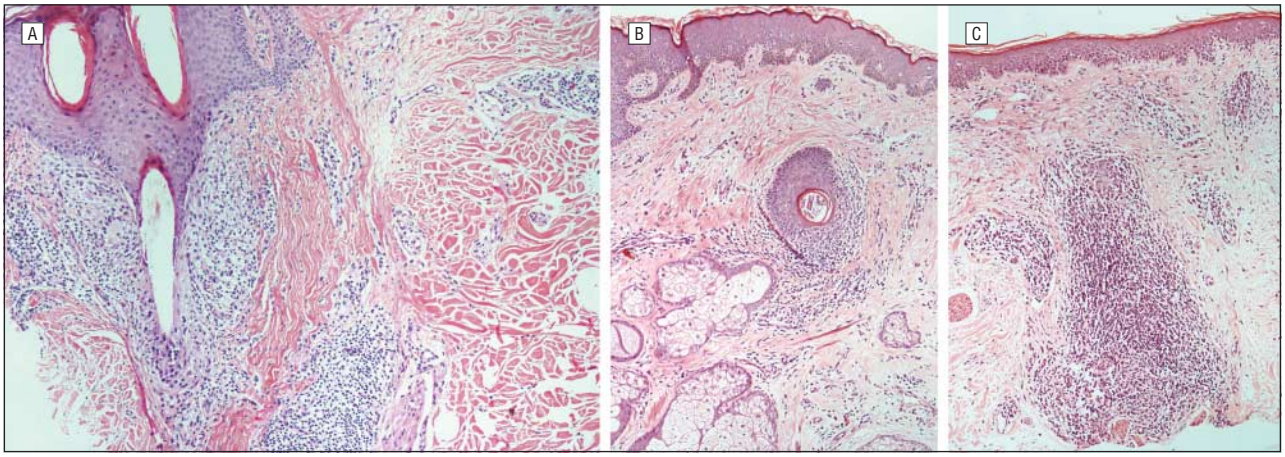

Figure 2. Results of histologic testing. A, Patient 1: scalp biopsy specimen showing perifollicular lichenoid infiltrate around terminal follicles (hematoxylin-eosin [HE], original magnification ×100, vertical sectioning). B, Patient 2: left preauricular region biopsy specimen showing perifollicular lichenoid infiltrate around vellus follicles (HE, original magnification ×100, horizontal sectioning). C, Patient 4: left temporal region biopsy specimen showing complete destruction of the vellus follicle (HE, original magnification ×100, vertical sectioning).

follicular epithelium at the isthmus level, and foreign body reaction to the hair shaft inside the dermis. Testing of preauricular specimens showed lichenoid reaction around the follicular infundibulum and isthmus and perifollicular fibrosis (Figure 2B). Both histologic patterns suggested LPP. Direct immunofluorescence of the scalp specimen showed moderate continuous and granulose anti-IgM fluorescence over the basement membrane and cytoid bodies in the papillary dermis. Over the face, DIF highlighted globular cytoid deposits of IgM and IgA in the dermis.

CASE 3

A 46-year-old black perimenopausal woman described loss of eyebrows and hair over the frontal hairline during the past year. A few months after the alopecic process started, she noticed progressive roughening of her facial skin (Figure 1D). Hair on her limbs had not been present for 5 years. Biopsies were performed in 3 different sites (frontal hairline, preauricular region, and right forearm). Histologic testing of scalp specimens showed decreased follicular density, chronic perifolliculitis, and perifollicular fibrosis. Skin from her face and arm showed similar findings, also characterizing an LPP alopecic process. Direct immunofluorescence was performed on the scalp and face specimens, and the results showed no abnormalities.

CASE 4

A 50-year-old white woman reported hair loss over her frontal hairline for 3 years, as well as decreased density of her eyebrows and eyelashes for 10 years. One year before this consultation, she noticed changes of her facial skin surface and loss of hair on her arms. She attributed both of these effects to hormonal changes (menopause 5 years before the visit to our clinic). Biopsies were per-

©2011 American Medical Association. All rights reserved.
Downloaded From: http://archderm.jamanetwork.com/ on 12/08/2013

formed on samples taken from her scalp, face, and arm. Histologic evaluation of scalp tissue detected chronic perifolliculitis with perifollicular fibrosis. The facial skin specimen showed intense lymphoplasmocytic infiltrate with complete destruction of the follicle and only remnants of the piloerector muscle and sebaceous gland (Figure 2C). A similar infiltrate surrounding a fibrous tract could be observed in the skin specimen from the arm. Negative results of DIF testing were observed in all specimens.

COMMENT

Frontal fibrosing alopecia is a specific form of scarring alopecia that affects the frontal hairline, most often in postmenopausal women.[4] Histologic characteristics of the affected area of the scalp include a follicle-centered lichenoid inflammatory process similar to that of LPP, and FFA is considered a clinical variant of LPP. Preferential involvement of vellus and intermediate hair follicles is supported by some authors.[5]

Eyebrows are affected in 50% to 75% of patients with FFA. Less frequently, eyelashes and hairs in the axilla or pubic area can also be affected.[6,7] Body vellus involvement has been recognized since 1997,[8] manifested almost always as noninflammatory diffuse hair loss. Localized involvement and follicular inflammatory signs, such as patchy alopecia, have been rarely described,[9] and keratotic papules, with minimal pruritus, have been reported only once.[2]

The incidence of nonscalp vellus involvement is not known, with published data showing great variation.[1,5,6,8] Involvement of facial vellus would be expected from the new concept of FFA as a more generalized disease, but that hypothesis has not yet been studied. The only publication[10] to report on a patient with FFA and a clinical presentation similar to that of our patients described "keratosis pilaris–like papules" over the forehead and cheeks, but the lesions were not biopsied and no histologic correlation with LPP was established.

To our knowledge, ours is the first report on the involvement of facial vellus of patients with FFA. Unlike the usual "silent" clinical presentation of the vellus involvement over other body areas, facial vellus LPP involvement can lead to surface changes that may be recognized both by patients and dermatologists.

The clinical picture of FFA involves follicular micropapules randomly distributed over the facial skin but readily more visible over the temporal regions. No particular inflammatory sign (ie, erythema or desquamation) is present, and facial vellus are decreased or absent. Proximities, such as inframandibular and retroauricular areas, may also be affected; this may help differentiate FFA from photodamage. Our patients referred to it as roughening of the facial skin but did not correlate it with their hair problem, usually attributing it to aging or menopause.

Histologic testing of facial vellus in these patients showed LLP features similar to scalp FFA and to the body vellus involvement shown in previous studies[1-3] and in 2 of our patients (patients 3 and 4). Correlation of clinical and pathological findings suggests that follicular papules correspond to inflamed vellus follicles; we recommend that this be the site of a biopsy in suspected cases of FFA.

No topical treatments were prescribed for the face area despite histologic findings of disease activity, but all patients received therapy with oral medications, such as prednisone, 0.5 mg/kg, which was then tapered to discontinuation, and antimalarials (hydroxychloroquine, 400 mg/d, or chloroquine diphosphate, 250 mg/d). After at least 6 months of this treatment, all patients reported improvement of their facial skin surface and the regrowth of vellus.

Similar to other FFA clinical features, the relationship between the change in facial skin and menopause varied greatly in our patients (4 years before or after menopause). The prevalence of this association is not known; however, because 4 patients with generalized FFA were seen in our hair clinic within a relatively short period, we believe it is underdiagnosed.

In conclusion, the concept of FFA as a generalized disease is important for treatment planning and research. Dermatologists must learn to recognize the subtle changes in facial skin surface of patients with FFA and discuss them with the patients, who may attribute this roughness to aging or hormonal changes of menopause. Further studies are needed to determine the prevalence of skin involvement in patients with FFA.

Accepted for Publication: July 19, 2011.
Correspondence: Aline Donati, MD, Department of Dermatology, University of São Paulo, Avenida Dr Enéas de Carvalho Aguiar, 255-3, Andar, Sala 3069, São Paulo, SP, Brazil 05403-900 (aline@donati.com.br).
Author Contributions: Drs Donati and Romiti had full access to all the data in the study and take responsibility for the integrity of the data and the accuracy of the data analysis. *Study concept and design:* Donati. *Acquisition of data:* Donati, Molina, and Doche. *Analysis and interpretation of data:* Donati, Valente, and Romiti. *Drafting of the manuscript:* Donati, Molina, Doche, and Romiti. *Critical revision of the manuscript for important intellectual content:* Valente and Romiti. *Administrative, technical, and material support:* Donati. *Study supervision:* Valente and Romiti.
Financial Disclosure: None reported.
Additional Contributions: Bruno Matard, MD (Centre Sabouraud, Paris, France), who first called Dr Donati's attention to this clinical pattern and its relation to FFA.

REFERENCES

1. Chew A-L, Bashir SJ, Wain EM, Fenton DA, Stefanato CM. Expanding the spectrum of frontal fibrosing alopecia: a unifying concept. *J Am Acad Dermatol.* 2010; 63(4):653-660.
2. Miteva M, Camacho I, Romanelli P, Tosti A. Acute hair loss on the limbs in frontal fibrosing alopecia: a clinicopathological study of two cases. *Br J Dermatol.* 2010;163(2):426-428.
3. Armenores P, Shiato K, Rein C, Sidhy S. Frontal fibosing alopecia associated with generalized hair loss. *Australas J Dermatol.* 2010;51(3):183-185.
4. Kossard S. Postmenopausal frontal fibrosing alopecia: scarring alopecia in a pattern distribution. *Arch Dermatol.* 1994;130(6):770-774.
5. Tosti A, Piraccini BM, Iorizzo M, Misciali C. Frontal fibrosing alopecia in postmenopausal women. *J Am Acad Dermatol.* 2005;52(1):55-60.
6. Moreno-Ramírez D, Camacho Martínez F. Frontal fibrosing alopecia: a survey in 16 patients. *J Eur Acad Dermatol Venereol.* 2005;19(6):700-705.
7. Samrao A, Chew A-L, Price V. Frontal fibrosing alopecia: a clinical review of 36 patients. *Br J Dermatol.* 2010;163(6):1296-1300.

©2011 American Medical Association. All rights reserved.
Downloaded From: http://archderm.jamanetwork.com/ on 12/08/2013

8. Kossard S, Lee M-S, Wilkinson B. Postmenopausal frontal fibrosing alopecia: a frontal variant of lichen planopilaris. *J Am Acad Dermatol*. 1997;36(1):59-66.
9. Faulkner CF, Wilson NJ, Jones SK. Frontal fibosing alopecia associated with cutaneous lichen planus in a premenopausal woman. *Australas J Dermatol*. 2002;43(1):65-67.
10. Tan KT, Messenger AG. Frontal fibrosing alopecia: clinical presentations and prognosis. *Br J Dermatol*. 2009;160(1):75-79.

Notable Notes

Tools of the Trade

This little birdie is completely made from items that I use in my daily practice as a dermatologist (**Figure**). It was originally supposed to be a peacock, but as it evolved (and given the season), I think that it's become more turkeylike. Whatever! Happy Holidays!

Figure. Head and neck, liquid nitrogen pressure gauge; eyes, liquid nitrogen nozzles; beak, needle holder; hair, hyfercator electrodessicator tips; body, stainless steel canister for holding odds and ends; chest, large cotton-tipped applicators; wings, disposable scalpels; tail feathers, disposable biopsy punches; legs, reusable punches; and feet, forceps.

Mark S. Bernhardt, MD

Contact Dr Bernhardt at 1601 E Broward Blvd, Ft Lauderdale, FL 33301 (cheesedb@aol.com).

©2011 American Medical Association. All rights reserved.
Downloaded From: http://archderm.jamanetwork.com/ on 12/08/2013