STUDY

Dermoscopic Characteristics of Congenital Melanocytic Nevi Affecting Acral Volar Skin

Akane Minagawa, MD; Hiroshi Koga, MD; Toshiaki Saida, MD, PhD

Objective: To characterize the dermoscopic features of acral congenital melanocytic nevi (CMN).

Design: Retrospective independent evaluation of dermoscopic images by 2 dermoscopists.

Setting: A dermatology clinic at a university hospital.

Patients: Using the files of the clinic from January 1, 2004, through February 28, 2009, we selected cases with CMN lesions affecting acral volar skin that were present at birth or developed within the first few months of life.

Main Outcome Measures: Characteristic dermoscopic features and their frequencies.

Results: We collected a total of 24 acral CMN lesions. Dermoscopically, 9 lesions (38%) showed a combination of the crista dotted pattern and the parallel furrow pattern. Of these 9 lesions, 1 also had a fibrillar pattern. The remaining 15 lesions showed the following single-component patterns: the parallel furrow pattern in 6 (25%), the crista dotted pattern in 3 (12%), the fibrillar pattern in 2 (8%), and the globular, globulostreaklike, nontypical, and parallel ridge patterns in 1 each (4%). We also followed up 6 lesions for several years. Changes in the dermoscopic features were observed in 4 CMN lesions from patients younger than 14 years. Three lesions had a combination of the crista dotted and parallel furrow patterns on the first visit that changed to the nontypical pattern; in addition, the degrees of pigmentation decreased during follow-up. In the remaining lesion, the globulostreaklike pattern changed to the parallel furrow pattern.

Conclusions: Most CMN lesions affecting acral volar skin show characteristic dermoscopic features distinguishable from acral melanoma. The combination of the crista dotted and parallel furrow patterns (ie, peas-in-a-pod pattern) is the most common feature in acral CMN. Some lesions of acral CMN fade during childhood.

Arch Dermatol. 2011;147(7):809-813

Dermoscopy is a noninvasive diagnostic method to evaluate pigmented and nonpigmented skin lesions. Many dermoscopic characteristics have been reported in various diseases, and some of these are indispensable for diagnosis. Dermoscopy is particularly useful in diagnosing pigmented skin lesions on acral volar skin, which is the most prevalent site of melanoma in nonwhite populations. Our group reported that melanoma and acquired melanocytic nevi (AMN) affecting acral volar skin show characteristic dermoscopic patterns, allowing the 2 categories to be easily differentiated.[1-3] We now believe that histopathologic examination is not needed for most AMN on acral volar skin when they show the typical benign dermoscopic patterns, that is, the parallel furrow, the latticelike, or the regular fibrillar pattern. Combining these dermoscopic data and the 7-mm criterion (biopsy of acral AMN >7 mm in diameter),[4] we proposed the 3-step algorithm for management of acral melanocytic lesions.[5,6] However, application of this algorithm is limited to AMN, and the validity of this algorithm for congenital melanocytic nevi (CMN) affecting acral volar skin has yet to be investigated.

In general, CMN is defined as a melanocytic nevus that is present at birth or becomes apparent shortly after birth.[7-9] The CMN lesions tend to be more diverse in size, color, and shape than AMN lesions. Therefore, a histopathologic examination is occasionally performed for CMN, especially when the lesion has a large diameter and/or is clinically or dermoscopically atypical, to allow differentiation from melanoma. Little is known about the dermoscopic features of CMN affecting acral volar skin. Clarification of the dermoscopic characteristics of acral CMN aids in the management of pigmented lesions on acral volar skin. Herein, we report the results of dermoscopic analysis of acral CMN.

Author Affiliations:
Department of Dermatology, Shinshu University School of Medicine (Drs Minagawa and Saida), and Clinical Trial Research Center, Shinshu University Hospital (Dr Koga), Matsumoto, Japan.

©2011 American Medical Association. All rights reserved.
Downloaded From: http://archderm.jamanetwork.com/ on 05/24/2013

Table. Definitions of Dermoscopic Patterns of Acral Melanocytic Lesions

Pattern	Definition	Source
Parallel furrow	Formed by pigmented parallel lines corresponding to furrows of the skin markings	Saida et al,[2] 1995
Latticelike	Composed of pigmented lines along and across furrows of the skin markings	Saida et al,[2] 1995
Fibrillar	Formed by densely packed, fibrillar pigmented lines arranged in the direction crossing the furrows	Saida et al,[2] 1995
Parallel ridge	Accentuated pigmentation on ridges of the skin markings	Oguchi et al,[1] 1998
Globular	Composed of dots and globules in an area of diffuse light brown pigmentation; in this pattern, a nonparallel distribution of globules was present	Malvehy and Puig,[10] 2004
Reticular	Consisting of reticulated pigmentation similar to the pigment network of nonglabrous skin; no lesion in this group presented a parallel furrow, fibrillar or filamentous, or latticelike pattern	Malvehy and Puig,[10] 2004
Homogeneous	Regular light brown pigmentation with no other distinctive feature	Malvehy and Puig,[10] 2004
Transition	Combines the dermoscopic features of a typical brown to black pigment network in one area of the lesion with the dermoscopic features of a parallel furrow or latticelike pattern in another part of the same lesion	Altamura et al,[11] 2006
Crista dotted	Composed of dots and globules regularly distributed on the ridges near openings of the eccrine ducts in a regular fashion	Saida et al,[3] 2002; Ikeda,[12] 1999
Globulostreaklike	A mottled appearance with round to oval bluish pigmented spots attached to irregular brownish pigmentation; pigmentation was annular or, in some cases, dotted and unrelated to the sulcus or crista superficialis	Ozdemir et al,[13] 2007
Nontypical	Cannot be classified into any other pattern	Saida et al,[2] 1995

METHODS

In this retrospective study, we examined the dermoscopic features of CMN affecting acral volar skin in cases seen at the Department of Dermatology, Shinshu University Hospital, from January 1, 2004, through February 28, 2009. Based on the medical history, we collected data on acral pigmented skin lesions that were present at birth or that developed within the first few months of life. All patients and/or their families gave informed consent for participation in this study. Images of the lesions were recorded by nonpolarized contact dermoscopy (Dermlite II Fluid; 3Gen, Dana Point, California), combined with a digital high-definition video camera recorder (HDR-HC3; Sony Co, Tokyo, Japan). Dermoscopic observations were made with slight pressure to the surface of the lesions after application of large amounts of ultrasound gel. The dermoscopic analysis was performed on a 24-inch flat-panel monitor (S2409W; Dell Inc, Austin, Texas). Each dermoscopic image was evaluated independently by 2 expert dermoscopists (A.M. and H.K.) and was classified as having the following dermoscopic patterns: parallel furrow, latticelike, fibrillar, homogeneous, globular, reticular, transition, globulostreaklike, crista dotted, and nontypical (**Table**).[1-3,10-13] The presence of the following dermoscopic features was also evaluated: fine reticulated background pigmentation, homogeneous pigmentation, irregular diffuse pigmentation, peripheral irregular dots and globules, abrupt edge, radial streaming, asymmetrical pseudopods, blotches, regression structures, blue-white veil, and polychromy. The 2 observers conferred on the presence of the features in cases in which their initial findings did not agree. Because the number of lesions evaluated was small, we performed qualitative analysis of the frequency of each dermoscopic feature. All the lesions were diagnosed as acral CMN with the clinical and anamnestic features. None of the lesions were examined histopathologically.

RESULTS

We examined a total of 24 acral CMN lesions in 24 Japanese patients (13 male and 11 female patients; mean age, 6.8 years [range, 0-27 years]). Of these, 18 lesions were present at birth and the remaining 6 developed within the first few months of life. None of the patients had a history of melanoma or other skin cancers. According to the classification of CMN by size,[14] 22 lesions were small (<1.5 cm in diameter) and the remaining lesions were of medium size (1.5-20.0 cm in diameter). The mean maximum diameter was 8.9 mm (range, 3.4-18.9 mm). Four lesions were found on the palm of the hand and 20 on the sole of the foot.

In the present study, the combination of the crista dotted (defined as dots/globules with a regular distribution on the ridges near the openings of the eccrine ducts) and parallel furrow patterns was most prevalent and was detected in 8 lesions (**Figure 1**). All 8 lesions were located on the sole of the foot. Another lesion, located on the volar aspect of the toe, showed a fibrillar pattern in addition to the combination of the crista dotted and parallel furrow patterns. Six lesions (25%) showed the parallel furrow pattern only, including 2 lesions each with the single line or double dotted line variant and 1 lesion each with the single dotted and the double line variants. Three lesions (12%) had the crista dotted pattern only. The fibrillar pattern was observed in 2 lesions (8%); one was located on the volar aspect of a finger and the other on the heel of the foot. The globular, globulostreaklike, nontypical (**Figure 2**), and parallel ridge patterns were observed in 1 lesion (4%) each. The patient with acral CMN exhibiting the parallel ridge pattern first visited our clinic at 21 years of age. Although the specificity of the parallel ridge pattern for melanoma is very high (99%),[1] this patient's lesion was diagnosed as acral CMN because it was present at birth and the clinical features showed no subsequent changes. Moreover, we did not detect any changes in the dermoscopic pattern of this lesion thereafter.

Homogeneous light brown background pigmentation was observed in 14 lesions in our series. Focal pig-

©2011 American Medical Association. All rights reserved.
Downloaded From: http://archderm.jamanetwork.com/ on 05/24/2013

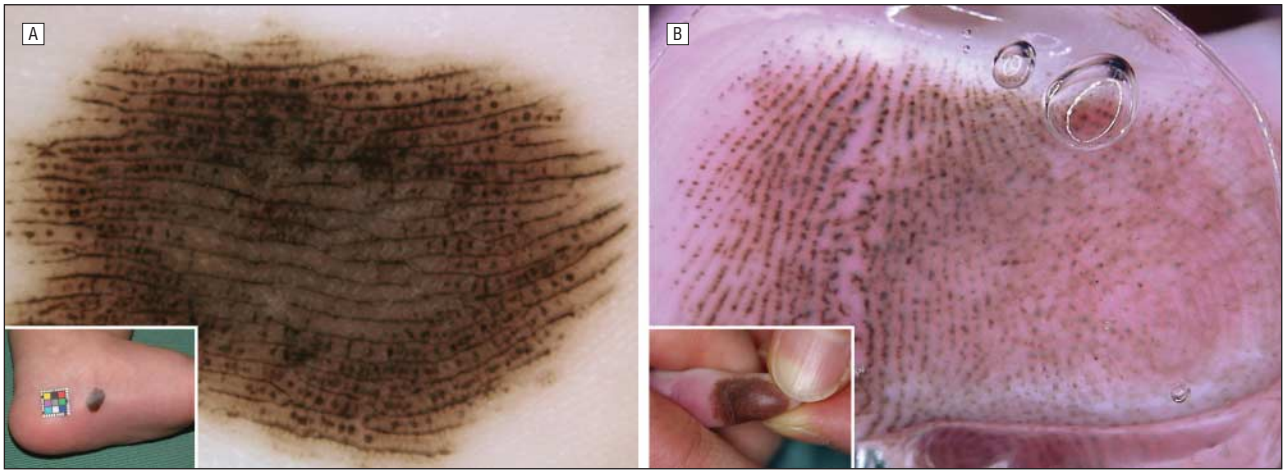

Figure 1. Clinical and dermoscopic features of congenital melanocytic nevi affecting acral volar skin. A, Clinical features include a brown macule, 5.6 × 9.5 mm in diameter, on the sole of the foot (inset) of a boy aged 5 months. Dermoscopic features include the combination of the crista dotted and parallel furrow patterns (ie, the peas-in-a-pod pattern) observed with homogeneous light brown background pigmentation (original magnification ×10). B, Clinical features include brown to gray macule, 6 × 12 mm in diameter, on the finger (inset) of a boy aged 3 months. Dermoscopic features include the crista dotted pattern (original magnification ×10).

mentation with dark brown tone was observed at the center of 2 lesions. None of the acral CMN lesions in our series showed the latticelike, the reticular, the homogeneous, or the transition pattern. Fine reticulated pigmentation was not observed in any of the lesions in our series. Furthermore, none of the lesions showed dermoscopic features of melanoma, such as irregular diffuse pigmentation, peripheral irregular dots/globules, abrupt edges, radial streaming, asymmetrical pseudopods, irregular blotches, regression structures, blue-white veil, or polychromy.

Follow-up for the clinical course of 6 lesions ranged from 7 months to 11 years. The dermoscopic features changed in 4 cases, and all these patients were younger than 14 years. Three cases showed the combination of the crista dotted and parallel furrow patterns on the first visit; however, the pattern changed into the nontypical pattern and the degree of pigmentation decreased during follow-up (**Figure 3**A-F). The fourth case, with a changing pattern, showed the globulostreaklike pattern at the first visit, which changed to the parallel furrow pattern 18 months later. In contrast, no changes were observed in the remaining 2 cases, which maintained the parallel ridge pattern (Figure 3G and H) and the parallel furrow pattern for 7 and 10 months, respectively.

COMMENT

Differentiation between early melanoma and melanocytic nevi is important. Many clinical and dermoscopic criteria have been proposed to allow such differentiation. For melanocytic lesions affecting acral volar skin, characteristic dermoscopic features have been well established in melanoma and in AMN.[1-6,10-13] However, little is known about the dermoscopic features of acral CMN. We found that the combination of the crista dotted and parallel furrow patterns was the most common dermoscopic feature in acral CMN. Furthermore, acral CMN tended to fade during childhood.

Figure 2. Dermoscopic features of a congenital melanocytic nevus on acral volar skin. Clinical features include a light brown macule, 8.0 × 12.5 mm in diameter, on the sole of the foot (inset) of a woman aged 27 years. Dermoscopic features include the nontypical pattern, characterized by mottled or noncircumscribed light brown pigmentation (original magnification ×10).

In the Japanese population, acral volar skin is the most prevalent site of melanoma, with about one-third of all cutaneous melanomas developing on acral volar skin.[15] On the other hand, melanocytic nevus is also prevalent in acral volar skin: 8% to 10.9% of the Japanese population have melanocytic nevi on the soles of the feet.[3,16] Thus, it is critical for Japanese dermatologists to differentiate between early melanoma and melanocytic nevi when they see brownish black macules on acral volar skin, and dermoscopy is very helpful in this differentiation.[6] Most cases of acral AMN exhibit the parallel furrow, the latticelike, or the fibrillar pattern, whereas most early acral melanomas show the parallel ridge pattern. However, to date, dermoscopic features of CMN affecting acral volar skin have not been elucidated, and dermoscopic indicators for differentiation between acral CMN and early acral melanoma remain to be clarified. Previously, the homogeneous blue pattern and the multicomponent pattern con-

©2011 American Medical Association. All rights reserved.
Downloaded From: http://archderm.jamanetwork.com/ on 05/24/2013

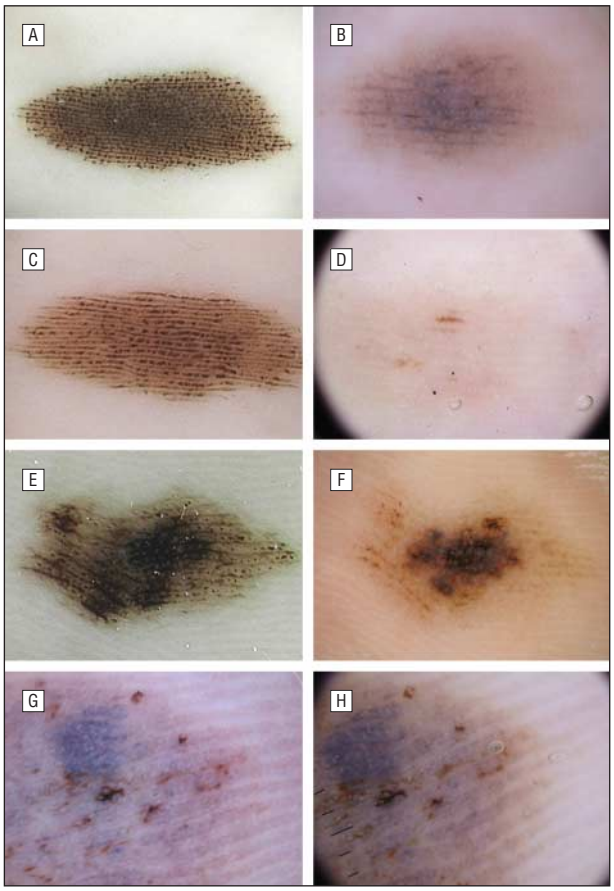

Figure 3. Acral congenital melanocytic nevi (CMN) during digital dermoscopic follow-up. The dermoscopic images in the left column (A, C, E, and G) represent the nevi at the first visit, whereas those in the right column (B, D, F, and H) represent the later images. Change over time is seen from the combination of the crista dotted and parallel furrow patterns (ie, the peas-in-a-pod pattern) (A and C) to the nontypical pattern with a decrease in pigmentation (B and D). Another change over time is seen from the peas-in-a-pod pattern with focal pigmentation (E) to the nontypical pattern with a decrease in pigmentation (F). In the acral CMN showing the parallel ridge pattern, no changes were observed over time (G and H). All lesions were located on the sole of the foot. Ages of the patients and diameters of the lesions were as follows: an infant aged 8 months with a lesion 3.5 × 10.0 mm (A); a child aged 6 years with a lesion 7.0 × 12.6 mm (B); a child aged 5 months with a lesion 3.5 × 8.7 mm (C); a child aged 4 years with a lesion 5.0 × 12.6 mm (D); a child aged 3 years with a lesion 4.8 × 8.5 mm (E); a child aged 11 years with a lesion 8.0 × 12.0 mm (F); an adult aged 21 years with a lesion 13.5 × 18.9 mm (F); and an adult aged 22 years with a lesion 13.6 × 22.4 mm (H) (original magnification ×10).

sisting of the parallel furrow, latticelike, and fibrillar patterns were documented as dermoscopic features of acral CMN.[17,18] In our series, 15 lesions exhibited the parallel furrow pattern, among which 6 showed only that pattern. In 8 lesions, the parallel furrow pattern was combined with the crista dotted pattern, and 1 lesion showed a combination of the parallel furrow, crista dotted, and fibrillar patterns. In addition, 2 lesions had the regular fibrillar pattern. These observations indicated that the dermoscopic features of acral CMN were common to those seen in AMN affecting acral volar skin; thus, most acral CMN are dermoscopically distinguishable from acral melanoma. One lesion showed the parallel ridge pattern, a highly characteristic dermoscopic pattern of acral melanoma. However, this lesion had been clinically stable for longer than 4 years, strongly suggesting that it was not an acral melanoma but a benign nevus. As reported in a previous study,[19] AMN on acral volar skin could show the parallel ridge pattern, although this is very rare. We recommend careful long-term follow-up in infants with a congenital acral lesion showing the parallel ridge pattern. We believe there is no need for hasty biopsy of such lesions in infants, and only periodic follow-up may be necessary.

The crista dotted pattern was another very common dermoscopic feature in acral CMN. Among the 24 acral CMN lesions, 12 (50%) showed the crista dotted pattern, including 8 cases with a combination of the crista dotted and parallel furrow patterns; 1 with the crista dotted, parallel furrow, and fibrillar patterns; and 3 with the crista dotted pattern alone. The frequent occurrence of the crista dotted pattern in acral CMN is in contrast with the lower incidence of this pattern in acral melanocytic nevi (1.3% to 2%).[3,16] The crista dotted pattern is characterized by regularly distributed dotted pigmentation mainly located near the orifice of the eccrine ducts.[3,12] The histopathological correlation of the crista dotted pattern is unclear, but the pattern suggests that nevus cell nests are situated around the eccrine ducts in the papillary dermis. This is an expected finding in CMN because adnexocentricity of nevus cells is one of the histopathological characteristics of CMN.

There may be some confusion in recognition of the crista dotted pattern; variants of this pattern could be interpreted as the fibrillar pattern.[20] Moreover, in our series, dots/globules of the crista dotted pattern in acral CMN were occasionally arranged very close to each other, producing features somewhat similar to the parallel ridge pattern. However, the pigmentation in the crista dotted pattern is not bandlike, as seen in the parallel ridge pattern, but more or less segmented and can thereby be differentiated from the authentic parallel ridge pattern.

The combination of the crista dotted and parallel furrow patterns was the most prevalent in our series. Some investigators[12,20] previously classified this combination as an independent pattern. Other researchers considered this to be the parallel furrow pattern associated with dots/globules or a variant of the latticelike pattern. We propose the term *peas-in-a-pod pattern* for this characteristic dermoscopic feature. The crista dotted and peas-in-a-pod patterns seem to be characteristic dermoscopic features of acral CMN, although further studies are required to determine the sensitivity and specificity of these patterns for acral CMN.

Altamura et al[21] reported dermoscopic changes over time in 18.3% of acral AMN, and the greatest frequency of changes (28.4%) occurred in patients 14 years or younger. In our series, dermoscopic changes over time were also observed in patients 14 years or younger. These data indicate that the dermoscopic features of congenital or acral AMN change frequently, particularly in patients 14 years or younger. Altamura et al[21] reported that only 3.1% of acral AMN showed a decrease in pigmentation during their digital follow-up. In contrast, in our series, 3 of 6 acral CMN lesions (50%) showed changes in the dermoscopic patterns, mostly in the nontypical pattern, along with a decrease in pigmentation. The prevalence of melanocytic nevi on the sole of the foot in the

©2011 American Medical Association. All rights reserved.
Downloaded From: http://archderm.jamanetwork.com/ on 05/24/2013

Japanese population was reported to be 3.30% at 0 to 6 years of age, 2.81% at 6 or 7 years of age, 3.72% at 12 or 13 years of age, and 17.30% at 20 to 39 years of age,[16,22] suggesting the possibility that acral CMN fades during childhood. The acral CMN lesions became larger over time in our series, but growth was proportional to increases in body size, and the numbers of furrows and ridges involved with the nevus lesions remained the same over time (unpublished data).

Although the nontypical pattern is defined as the unclassified type to any typical patterns, it includes dermoscopic features previously described as mottled or diffuse pigmentation, noncircumscribed blue to brown pigmentation, or monotonous diffuse pigmentation.[3,10] The nontypical pattern is more commonly seen in congenital nevi because an intradermal component is often predominant in CMN even on acral volar skin. In our series, 3 acral CMN with the peas-in-a-pod pattern changed into the nontypical pattern during observation. We suppose that some of the acral CMN lesions with the nontypical pattern are in the process of disappearing.

In conclusion, the combination of the crista dotted and parallel furrow patterns (ie, the peas-in-a-pod pattern) is a common characteristic dermoscopic feature in CMN affecting acral volar skin. The dermoscopic findings revealed in the present study aid in differentiating acral CMN not only from acral AMN but also from acral melanoma.

Accepted for Publication: June 15, 2010.
Correspondence: Hiroshi Koga, MD, Clinical Trial Research Center, Shinshu University Hospital, 3-1-1 Asahi, Matsumoto 390-8621, Japan (koga@shinshu-u.ac.jp).
Author Contributions: Drs Minagawa and Koga had full access to all the data in the study and take responsibility for the integrity of the data and the accuracy of the data analysis. *Study concept and design:* Minagawa and Saida. *Acquisition of data:* Minagawa. *Analysis and interpretation of data:* Minagawa, Koga, and Saida. *Drafting of the manuscript:* Minagawa and Saida. *Critical revision of the manuscript for important intellectual content*: Koga and Saida. *Study supervision:* Koga and Saida.
Financial Disclosure: None reported.

REFERENCES

1. Oguchi S, Saida T, Koganehira Y, Ohkubo S, Ishihara Y, Kawachi S. Characteristic epiluminescent microscopic features of early malignant melanoma on glabrous skin: a videomicroscopic analysis. *Arch Dermatol*. 1998;134(5):563-568.
2. Saida T, Oguchi S, Ishihara Y. In vivo observation of magnified features of pigmented lesions on volar skin using video macroscope: usefulness of epiluminescence techniques in clinical diagnosis. *Arch Dermatol*. 1995;131(3):298-304.
3. Saida T, Oguchi S, Miyazaki A. Dermoscopy for acral pigmented skin lesions. *Clin Dermatol*. 2002;20(3):279-285.
4. Saida T, Yoshida N, Ikegawa S, Ishihara K, Nakajima T. Clinical guidelines for the early detection of plantar malignant melanoma. *J Am Acad Dermatol*. 1990; 23(1):37-40.
5. Saida T. Dermoscopy: revolutionary method of diagnosis for melanoma. *Gan To Kagaku Ryoho*. 2009;36(4):573-576.
6. Saida T, Koga H. Dermoscopic patterns of acral melanocytic nevi: their variations, changes, and significance. *Arch Dermatol*. 2007;143(11):1423-1426.
7. Rook A, Burns T. *Rook's Textbook of Dermatology*. 7th ed. Malden, MA: Blackwell Science; 2004.
8. Maize JC, Ackerman AB. *Pigmented Lesions of the Skin: Clinicopathologic Correlations*. Philadelphia, PA: Lea & Febiger; 1987.
9. Marghoob AA, Braun RP, Kopf AW. *Atlas of Dermoscopy*. London, England: Taylor & Francis; 2005.
10. Malvehy J, Puig S. Dermoscopic patterns of benign volar melanocytic lesions in patients with atypical mole syndrome. *Arch Dermatol*. 2004;140(5):538-544.
11. Altamura D, Altobelli E, Micantonio T, Piccolo D, Fargnoli MC, Peris K. Dermoscopic patterns of acral melanocytic nevi and melanomas in a white population in central Italy. *Arch Dermatol*. 2006;142(9):1123-1128.
12. Ikeda S. Dermatoscopic findings of pigmented skin lesions [in Japanese]. *Jpn J Dermatol*. 1999;109(10):1417-1429.
13. Ozdemir F, Karaarslan IK, Akalin T. Variations in the dermoscopic features of acquired acral melanocytic nevi. *Arch Dermatol*. 2007;143(11):1378-1384.
14. Kopf AW, Bart RS, Hennessey P. Congenital nevocytic nevi and malignant melanomas. *J Am Acad Dermatol*. 1979;1(2):123-130.
15. Ishihara K, Saida T, Otsuka F, Yamazaki N; Prognosis and Statistical Investigation Committee of the Japanese Skin Cancer Society. Statistical profiles of malignant melanoma and other skin cancers in Japan: 2007 update. *Int J Clin Oncol*. 2008;13(1):33-41.
16. Kogushi-Nishi H, Kawasaki J, Kageshita T, Ishihara T, Ihn H. The prevalence of melanocytic nevi on the soles in the Japanese population. *J Am Acad Dermatol*. 2009;60(5):767-771.
17. Garrido-Ríos AA, Carrera C, Puig S, Aguilera P, Salerni G, Malvehy J. Homogeneous blue pattern in an acral congenital melanocytic nevus. *Dermatology*. 2008; 217(4):315-317.
18. Zalaudek I, Zanchini R, Petrillo G, Ruocco E, Soyer HP, Argenziano G. Dermoscopy of an acral congenital melanocytic nevus. *Pediatr Dermatol*. 2005;22(3):188-191.
19. Saida T, Miyazaki A, Oguchi S, et al. Significance of dermoscopic patterns in detecting malignant melanoma on acral volar skin: results of a multicenter study in Japan. *Arch Dermatol*. 2004;140(10):1233-1238.
20. Akasu R, Sugiyama H, Araki M, Ohtake N, Furue M, Tamaki K. Dermatoscopic and videomicroscopic features of melanocytic plantar nevi. *Am J Dermatopathol*. 1996;18(1):10-18.
21. Altamura D, Zalaudek I, Sera F, et al. Dermoscopic changes in acral melanocytic nevi during digital follow-up. *Arch Dermatol*. 2007;143(11):1372-1376.
22. Hayashida S, Hosokawa C, Hachisuka Z, et al. Prevalence and disappearance of childhood nevi on the hands and feet: cohort study of young children on Ishigaki Island [in Japanese]. *Jpn J Dermatol*. 2008;118(1):37-42.

©2011 American Medical Association. All rights reserved.
Downloaded From: http://archderm.jamanetwork.com/ on 05/24/2013