Safety of Oxybenzone: Putting Numbers Into Perspective

Oxybenzone, an organic UV-B and short-wave UV-A filter, has been available for over 40 years[1]; it is widely used in sunscreens and other consumer products in the United States.[2] The Centers for Disease Control and Prevention has estimated the prevalence of oxybenzone exposure in the general US population to be 96.8%.[3] In the past few years, oxybenzone has received increasing attention as a potentially harmful compound. Initial concerns arose when a report demonstrated systemic absorption of oxybenzone in humans at a rate of 1% to 2% after topical application.[4] Similar or higher rates of cutaneous absorption in human subjects have been observed.[5-9] The potential for biological effects, however, were first published in a study by Schlumpf et al[10] demonstrating uterotropic effects in immature rats after oral administration of oxybenzone; it should be noted that the estrogenic effect detected was less than 1 million-fold of estradiol, the positive control used. Nonetheless, this study has served as the basis for considerable concern among the public.

In assessing the potential for hormonal disruption in humans, we decided to place into perspective the doses of oxybenzone used by Schlumpf et al[10] to achieve the 23% increase in uterine size reported in immature rats. We performed 2 calculations: (1) we determined the equivalent amount of sunscreen required to be used topically in humans to achieve the effective cumulative amount of oxybenzone orally administered to immature rats; and (2) we determined the number of years of daily application required to obtain the equivalent levels of oxybenzone that the experimental animals were exposed to.

Methods. The oral dose of oxybenzone used by Schlumpf et al[10] was 1525 mg/kg/d over a 4-day period. The effective cumulative dose was 6100 mg/kg. To calculate an equivalent amount of sunscreen, the following assumptions were applied to the formula: (1) the weight of an average woman in the United States was assumed to be 74.6 kg[11]; (2) the absorption rate of topically applied oxybenzone, 10%, was assumed to be approximately 2%[4-9]; and (3) the maximum concentration of oxybenzone in sunscreen sold within the United States was assumed to be 6% (wt/vol), or 60 mg/mL.[12]

$$([6100 \text{ mg of Oxybenzone/kg} \times 74.6 \text{ kg}]/2\%) \times (1 \text{ mL of Sunscreen/60 mg of Oxybenzone}) = 379\,217 \text{ mL}$$

We then calculated the number of years of daily application that would be required to apply 379 217 mL of sunscreen under 3 different scenarios:

Scenario 1: 100% body surface area (BSA) coverage at a standard dose of 2 mg/cm^2 would require 30 mL (10 950 mL/y with daily application).

Scenario 2: 100% BSA coverage at a dose of 1 mg/cm^2 would requires 15 mL (5475 mL/y).

Scenario 3: 25% BSA coverage at a dose of 1 mg/cm^2 would require 3.75 mL (1369 mL/y).

Table. Years of Daily Sunscreen Application Required by an Average US Woman to Reach Systemic Levels of Oxybenzone per Unit of Body Mass Equivalent to Those Given to Immature Rats[10]

Characteristic	Scenario 1	Scenario 2	Scenario 3
Body surface area covered, %	100	100	25
Application dose, mg/cm^2/d	2	1	1
Application amount required, mL/d	30.00	15.00	3.75
Time required, y	34.6	69.3	277.0

For the purposes of this estimation, a generous in-use dose of 1 mg/cm^2 was used,[13-16] and it was assumed that coverage of 25% of the human BSA was limited to the face, neck, hands, and arms.[17]

Results. The numbers of years of daily application required to obtain the equivalent amount of sunscreen under the 3 scenarios are listed in the **Table**.

Comment. Our results indicate that both the application regimens and time periods required to obtain systemic levels of oxybenzone equivalent per unit of body mass are essentially unattainable. Our assumption is more conservative. For instance, the bioavailability of the oxybenzone-containing rat chow used by Schlumpf et al[10] may not have been 100%, and we did not take into account the excretion of oxybenzone in humans. In fact, oxybenzone has not been demonstrated to accumulate in the plasma even after several days of topical application.[6,9,18] Most relevant to this discussion, however, is that in a human study, oxybenzone did not demonstrate significant endocrine disruption, even with application of a formulation containing 10% oxybenzone.[6] In fact, after 40 years of use, we are not aware of any published study that demonstrates acute toxic effects in humans with systemic absorption of oxybenzone.

We do not intend for this exercise to serve as a basis from which to legitimize the extrapolation of data from immature rats to humans. In fact, basic scientific principles regarding the complexities of each respective biological system preclude this. Nonetheless, we hope that this analysis helps to place into perspective the doses reported by the in vivo study from which inappropriate conclusions have been drawn and considerable controversy has developed.

Steven Q. Wang, MD
Mark E. Burnett, BS
Henry W. Lim, MD

Accepted for Publication: November 30, 2010.
Author Affiliations: Dermatology Service, Memorial Sloan-Kettering Cancer Center, New York, New York (Dr Wang and Mr Burnett); Henry Ford Hospital, Detroit, Michigan (Dr Lim).
Correspondence: Dr Wang, Dermatology Service, Memorial Sloan-Kettering Cancer Center, 136 Mountain View Blvd, Basking Ridge, NJ 07920 (wangs@mskcc.org).
Author Contributions: All authors had full access to all of the data in the study and take responsibility for the

©2011 American Medical Association. All rights reserved.
Downloaded From: http://archderm.jamanetwork.com/ on 05/23/2013

integrity of the data and the accuracy of the data analysis. *Study concept and design:* Wang and Burnett. *Acquisition of data:* Wang and Burnett. *Analysis and interpretation of data:* Burnett and Lim. *Drafting of the manuscript:* Wang and Burnett. *Critical revision of the manuscript for important intellectual content:* Wang, Burnett, and Lim. *Statistical analysis:* Lim. *Study supervision:* Wang and Lim.

Financial Disclosure: None reported.

1. Food and Drug Administration. Sunscreen drug products for over-the-counter human use: tentative final monograph: proposed rule. *Fed Regist*. 1993;58(90):28194-28302.
2. National Library of Medicine. *Household Products Database*. Bethesda, MD: National Institutes of Health; 2010.
3. Calafat AM, Wong LY, Ye X, Reidy JA, Needham LL. Concentrations of the sunscreen agent benzophenone-3 in residents of the United States: National Health and Nutrition Examination Survey 2003-2004. *Environ Health Perspect*. 2008;116(7):893-897.
4. Hayden CG, Roberts MS, Benson HA. Systemic absorption of sunscreen after topical application. *Lancet*. 1997;350(9081):863-864.
5. Sarveiya V, Risk S, Benson HA. Liquid chromatographic assay for common sunscreen agents: application to in vivo assessment of skin penetration and systemic absorption in human volunteers. *J Chromatogr B Analyt Technol Biomed Life Sci*. 2004;803(2):225-231.
6. Janjua NR, Mogensen B, Andersson AM, et al. Systemic absorption of the sunscreens benzophenone-3, octyl-methoxycinnamate, and 3-(4-methylbenzylidene) camphor after whole-body topical application and reproductive hormone levels in humans. *J Invest Dermatol*. 2004;123(1):57-61.
7. Gustavsson Gonzalez H, Farbrot A, Larkö O. Percutaneous absorption of benzophenone-3, a common component of topical sunscreens. *Clin Exp Dermatol*. 2002;27(8):691-694.
8. Jiang R, Roberts MS, Collins DM, Benson HA. Absorption of sunscreens across human skin: an evaluation of commercial products for children and adults. *Br J Clin Pharmacol*. 1999;48(4):635-637.
9. Gonzalez H, Farbrot A, Larkö O, Wennberg AM. Percutaneous absorption of the sunscreen benzophenone-3 after repeated whole-body applications, with and without ultraviolet irradiation. *Br J Dermatol*. 2006;154(2):337-340.
10. Schlumpf M, Cotton B, Conscience M, Haller V, Steinmann B, Lichtensteiger W. In vitro and in vivo estrogenicity of UV screens. *Environ Health Perspect*. 2001;109(3):239-244.
11. Ogden CL, Fryar CD, Carroll FC, Flegal KM. Advance data from Vital and Health Statistics: Mean body weight, height, and body mass index, United States 1960-2002. http://www.cdc.gov/nchs/data/ad/ad347.pdf. Accessed April 26, 2011.
12. Food and Drug Administration. Sunscreen drug products for over-the-counter human use: final monograph, final rule. *Fed Regist*. 1999;64(98):27666-27693.
13. Wulf HC, Stender IM, Lock-Andersen J. Sunscreens used at the beach do not protect against erythema: a new definition of SPF is proposed. *Photodermatol Photoimmunol Photomed*. 1997;13(4):129-132.
14. Bech-Thomsen N, Wulf HC. Sunbathers' application of sunscreen is probably inadequate to obtain the sun protection factor assigned to the preparation. *Photodermatol Photoimmunol Photomed*. 1992-1993;9(6):242-244.
15. Neale R, Williams G, Green A. Application patterns among participants randomized to daily sunscreen use in a skin cancer prevention trial. *Arch Dermatol*. 2002;138(10):1319-1325.
16. Autier P, Boniol M, Severi G, Doré JF; European Organization for Research and Treatment of Cancer Melanoma Co-operative Group. Quantity of sunscreen used by European students. *Br J Dermatol*. 2001;144(2):288-291.
17. Lund CC, Broder NC. Estimation of areas of burns. *Surg Gynecol Obstet*. 1944;79:352-358.
18. Janjua NR, Kongshoj B, Andersson AM, Wulf HC. Sunscreens in human plasma and urine after repeated whole-body topical application. *J Eur Acad Dermatol Venereol*. 2008;22(4):456-461.

Open Pores With Plugs in Porokeratosis Clearly Visualized With the Dermoscopic Furrow Ink Test: Report of 3 Cases

Porokeratosis is an autosomal dominantly inherited disorder characterized by brown annular lesions with scaling ridges, which histopathologically corresponds to the cornoid lamella. Several dermoscopic findings of porokeratosis have been reported, including a whitish peripheral rim, brown globules and/or dots, red dots and/or red lines, and scarlike structures in the center of the lesions.[1] Herein, we report 3 cases of porokeratosis of Mibelli dermoscopically clearly showing multiple pores.

Report of 3 Cases. *Case 1*. An 88-year-old man presented with a 30-year history of multiple brown plaques. No family history of porokeratosis was reported. Clinical examination revealed that brown, round, sharply demarcated annular plaques up to 3 cm in size were widespread on the trunk and extremities (**Figure 1**). Dermoscopic evaluation of the lesions showed a brown rim along on periphery of the lesions (**Figure 2**A). The fine pigment network, dots and/or globules, and the small shining white or brown spots were mainly observed within the brown band.

Staining of the skin surface with whiteboard marker (the *furrow ink test*) clearly revealed the rims along the inside and outside of the peripheral band and multiple open pores with keratotic plugs (Figure 2B). Furthermore, the furrow ink test highlighted the differences in texture on the skin surface in some lesions. The texture was diminished and flattened in the periphery and finer in the central portion of the lesions compared with normal skin. Some pores corresponded to hair openings, which were confirmed pathologically (**Figure 3** and **Figure 4**). Although the pores were observed in almost all lesions, the number and distribution varied in each lesion.

Case 2. An 89-year-old man presented with a 2-year history of multiple brown plaques. Clinical examination revealed brown, sharply demarcated annular plaques up to 2 cm in size on the extremities. Dermoscopically, the multiple small brown spots were observed in the central area. Pathologic findings showed a column of compact hyperkeratosis with parakeratosis in the part corresponding to acrosyringium as well as typical cornoid lamella in the periphery of the lesion.

Case 3. A 52-year-old man presented with a 1-year history of multiple brown plaques. Clinical examination revealed light-brown, round, sharply demarcated plaques on the extremities. Dermoscopic findings were similar to those in cases 1 and 2, except with fewer pores.

Comment. Dermoscopic examination in our cases showed that the multiple pores seemed to correspond to hair openings and sweat pores. Porokeratosis of Mibelli was originally believed to involve columns of parakeratosis, the cornoid lamella, emerging only from the ostia of eccrine ducts. However, Reed and Leone[2] later proposed that the cornoid lamella did not originate from the ostia of ec-

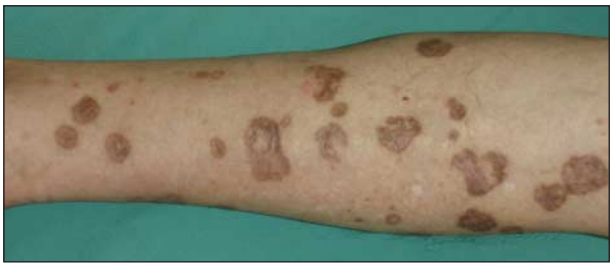

Figure 1. Case 1. Brown, round, sharply demarcated plaques on the leg.

©2011 American Medical Association. All rights reserved.
Downloaded From: http://archderm.jamanetwork.com/ on 05/23/2013