STUDY

Nodular Amyloidosis

Review and Long-term Follow-up of 16 Cases

Alison O. Moon, MD; Kenneth T. Calamia, MD; John S. Walsh, MD

Objectives: To review the clinical presentations of nodular amyloidosis, examine these cases for evidence of plasma cell monoclonality, and obtain long-term follow-up data on progression to systemic amyloidosis.

Design: Retrospective case series with long-term follow-up data obtained by phone survey.

Setting: Mayo Clinic, Rochester, Minn, and Mayo Clinic, Jacksonville, Fla.

Patients: All patients diagnosed with nodular amyloidosis between 1971 and 2001.

Main Outcome Measures: Clinical records and histopathologic characteristics were reviewed. Polymerase chain reaction to assess immunoglobulin gene rearrangement and immunohistochemical analysis to detect κ and λ light chain restriction were performed on paraffin-embedded specimens. Patients were contacted by phone to determine if progression to systemic disease had occurred.

Results: We identified 16 patients with nodular amyloidosis. Mean age at diagnosis was 60.8 years (range, 41-87 years). Eight (50%) of 16 patients had acral involvement. Immunohistochemical analysis demonstrated light chain restriction in 6 of 10 patients. At the time of diagnosis, no patient was known to have systemic amyloidosis. One patient, however, had a serum monoclonal λ protein and died 4 years later secondary to systemic amyloidosis. Follow-up data were obtained in 14 of the remaining 15 patients, with a mean follow-up time of 10 years (range, 8 months to 24 years). None of the 14 patients had signs or symptoms suggesting progression to systemic amyloidosis.

Conclusions: Nodular amyloidosis affects both sexes during middle age, with a tendency to affect acral sites. The relatively high rate of light chain restriction in our series provides further evidence for the presence of a local plasma cell clone. Progression to systemic amyloidosis is uncommon.

Arch Dermatol. 2003;139:1157-1159

From the Mayo Clinic, Jacksonville, Fla. The authors have no relevant financial interest in this article.

PRIMARY CUTANEOUS amyloidosis refers to amyloidosis involving the skin with no evidence of systemic involvement. It most commonly takes the form of either macular or lichen amyloidosis, in which the amyloid protein in the superficial dermis is composed of altered keratin filaments derived from degenerated keratinocytes.[1] In the less common nodular amyloidosis (primary nodular cutaneous amyloidosis), the amyloid is derived from immunoglobulin light chains (AL protein) produced by local plasma cells. Systemic amyloidosis may be associated with a number of types of skin lesions, including nodular lesions, which may be clinically and histologically identical to those seen in primary nodular cutaneous amyloidosis. Progression of nodular amyloidosis to systemic amyloidosis has been reported to occur in 7% to 50% of patients.[2,3] Our goal was to review the clinical presentations of patients with nodular amyloidosis, examine these cases for evidence of plasma cell monoclonality, and obtain long-term follow-up data on progression to systemic disease.

METHODS

Patients with biopsy-proven nodular amyloidosis seen between January 1971 and February 2001 were identified by accessing computer-generated master diagnosis lists, dermatopathology records, and surgical databases. The clinical records and available histopathologic findings were reviewed. Immunohistochemical stainings for κ and λ light chains as well as polymerase chain reaction (PCR) analyses for immunoglobulin gene rearrangement were performed on sections obtained from available paraffin blocks. Patients (or if deceased, their spouses or first-degree relatives) were contacted by phone survey in October 2001 to determine if progression to systemic disease had occurred. The institutional review board of the Mayo Foundation approved this study.

©2003 American Medical Association. All rights reserved.
Downloaded From: http://archderm.jamanetwork.com/ on 05/22/2013

Clinical and Laboratory Data and Follow-up Period of Study Patients

Patient No./ Sex/Age at Diagnosis, y	Duration Before Diagnosis	Affected Site(s)	Workup at Time of Diagnosis	Follow-up Period	Light Chain Restriction
1/F/48	2 y	Cheek, trunk, thigh	(–) SPEP, IEP, rectal biopsy, bone marrow biopsy	22 y 9 mo	κ Restriction
2/M/61	2 y 6 mo	Toes, web spaces	(–) ECG, SPEP at another institution; patient declined further workup	Lost to follow-up	Indeterminate
3/F/62	17 y	Soles, buttock, forearm	(–) SPEP, IEP, rectal biopsy	24 y	No
4/M/47	2 mo	Nose	(–) SPEP, UPEP, IEP	17 y	κ Restriction
5/M/65	Recent onset	Preauricular cheek	(–) SPEP, ECG	5 y 4 mo	λ Restriction
6/F/46	1 y	Neck, trunk, forehead	(–) UPEP, IEP, rectal biopsy, fat aspirate, ECG, bone marrow biopsy	10 y 5 mo	κ Restriction
7/M/79	4 mo	Chonchal bowl	(–) Fat aspirate, SPEP, UPEP, IEP, ECG	5 y 1 mo	No
8/F/87	Recent onset	Perineum	(+) Monoclonal IgGλ on IEP, (–) echocardiogram	Died of systemic disease after 3 y 9 mo	Not performed
9/F/57	Recent onset	Chest	(–) SPEP, IEP	12 y 6 mo	κ Restriction
10/F/66	1 y	Abdomen	(–) SPEP, IEP, UPEP, echocardiogram	13 y 5 mo	Not performed
11/F/64	6 mo	Labia, perineum, buttock	(–) SPEP, IEP, UPEP, fat aspirate, bone marrow biopsy	9 y 6 mo	Not performed
12/F/47	2 y 6 mo	Buttock	(–) Fat aspirate, SPEP, IEP, UPEP, echocardiogram	7 y 2 mo	Not performed
13/M/41	9 y	Nose, chin	(–) SPEP, UPEP, IEP, fat aspirate, bone marrow biopsy	6 y 5 mo	Not performed
14/M//69	37 y	Sole, medial toe	(–) SPEP, UPEP, bone marrow biopsy, fat aspirate	2 y	Indeterminate
15/M/59	8 y	Nasal tip, nasal sidewall	(–) IEP, SPEP, fat aspirate	4 y 5 mo	Not performed
16/F/75	2 y	Trunk, arms	(–) SPEP, IEP	8 mo	λ Restriction

Abbreviations: ECG, electrocardiogram; IEP, immunoelectrophoresis; SPEP, serum protein electrophoresis; UPEP, urine protein electrophoresis.

RESULTS

Of the 16 patients identified (**Table**), there were 9 women and 7 men. The mean age at diagnosis was 60.8 years (range, 41-87 years), and the mean duration of the lesions before diagnosis was 13.5 years (range, 6 months to 30 years). There was a tendency for acral involvement, with lesions occurring on the feet, nose, or periauricular area in 8 of 16 patients (**Figure 1** and **Figure 2**). No patient had a family history of amyloidosis. Two patients had Sjögren syndrome, 2 patients had type 2 diabetes mellitus, and 3 patients had liver disease (1 case each of Gilbert syndrome, primary biliary cirrhosis, and steatohepatitis of unknown cause). Of 10 patients with paraffin blocks available, 4 demonstrated a κ light chain restriction and 2 showed a λ light chain restriction, suggesting local plasma cell clonality (**Figure 3** and **Figure 4**). PCR analysis for immunoglobulin gene rearrangement performed on the same 10 available paraffin blocks showed no amplifiable DNA in 7 of 10 patients despite adequate controls. In the remaining 3 patients, the PCR results were technically suboptimal because the control primer failed to amplify.

At the time of initial skin biopsy, 1 patient was noted to have a serum monoclonal IgGλ protein, but she was not extensively evaluated for the possibility of systemic amyloidosis. She developed the first symptoms (edema, dyspnea, and fatigue) of systemic amyloidosis within the following year. She subsequently died, at age 90 years, 5 months after a lung biopsy confirmed interstitial amyloidosis. Results of telephone surveys of the remaining 15 patients revealed that 14 had no diagnosis or symptoms suggesting progression to systemic disease after a mean follow-up of 10 years (range, 8 months to 24 years). One patient was lost to follow-up.

COMMENT

We identified 16 cases of nodular amyloidosis. The disorder affected both sexes in middle age to late adulthood, with a predilection for acral sites. Two of our patients had Sjögren syndrome. A possible association of nodular amyloidosis and Sjögren syndrome has been reported.[4] The presence of light chain restriction in our series provides further evidence for a monoclonal population of plasma cells producing the amyloid protein. The negative PCR finding for immunoglobulin gene rearrangement in 7 of the 10 specimens with adequate controls may be the consequence of too few plasma cells present to extract a sufficient amount of DNA to amplify a clone. Although plasma cell monoclonality using PCR on paraffin-embedded sections has been reported, the sensitivity of PCR on paraffin-embedded tissue is unknown.[5-7]

In our follow-up study, diagnosis of systemic amyloidosis occurred within 1 year in a single patient who had a monoclonal protein in the serum at the time of her skin biopsy. This patient may have had unrecognized systemic amyloidosis from the onset. In 14 other patients, there was no progression to systemic disease.

Serum amyloid P component is a normal circulating plasma protein that binds specifically to amyloid fibrils.[8] Scintigraphy with iodine 123–labeled serum amyloid P component may be useful in monitoring patients with nodular amyloidosis and a monoclonal gammopathy for early occult systemic amyloidosis.[9]

©2003 American Medical Association. All rights reserved.
Downloaded From: http://archderm.jamanetwork.com/ on 05/22/2013

Figure 1. Preauricular waxy plaque of nodular amyloidosis.

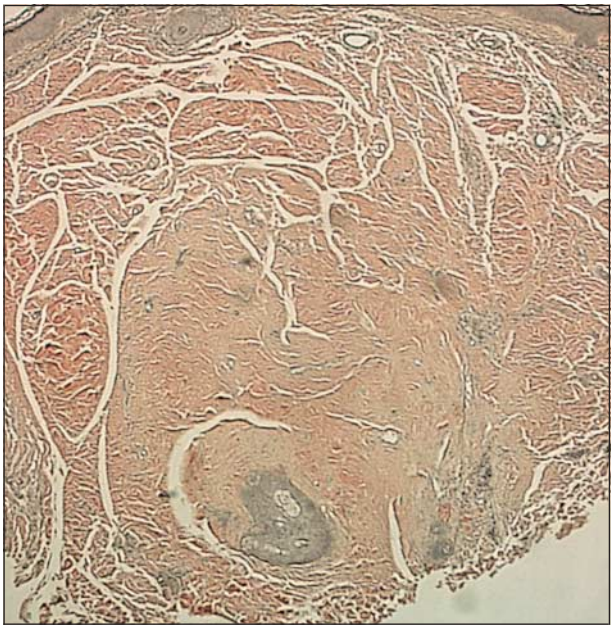

Figure 2. Histopathologic photomicrograph showing nodular amyloidosis (hematoxylin-eosin, original magnification ×40).

In another case series of nodular amyloidosis with long-term follow-up, 1 patient of 15 developed a trace IgGκ paraproteinemia 5 years after his initial diagnosis of nodular amyloidosis with a negative serum protein electrophoresis finding.[3] He eventually developed biopsy-proven amyloid nodules of the larynx with possible cardiac involvement as well. In a 1970 study by Brownstein and Helwig,[2] 5 of 10 patients who initially appeared to have localized "tumefactive" or nodular amyloidosis were subsequently found to have evidence of systemic amyloidosis. Unfortunately, no details regarding initial laboratory investigations or follow-up periods were provided. Our experience suggests that the progression of nodular amyloidosis to systemic amyloidosis is uncommon, particularly if no clinical or laboratory evidence for systemic disease exists at the time of diagnosis.

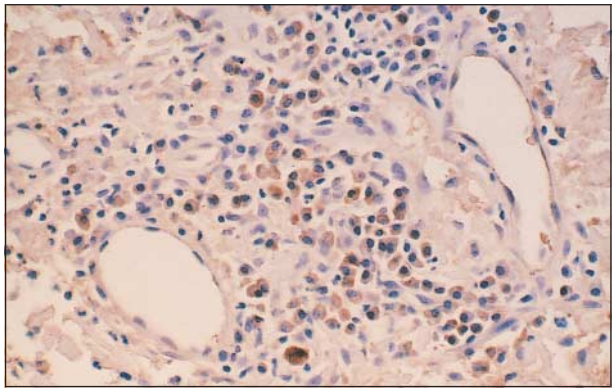

Figure 3. Positive staining for κ light chains (κ light chain immunoperoxidase, original magnification ×200).

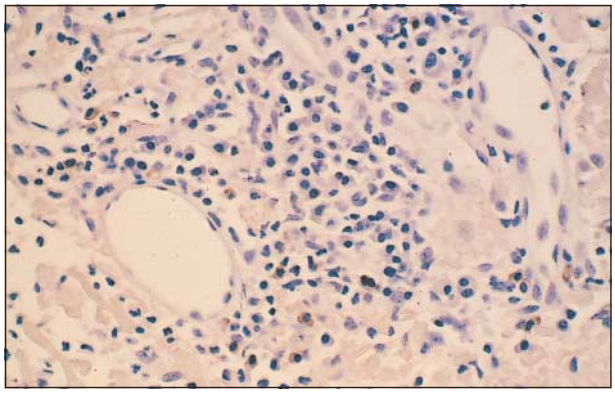

Figure 4. Negative staining for λ light chains (λ light chain immunoperoxidase, original magnification ×200; same field as Figure 3).

Accepted for publication March 19, 2003.

Corresponding author and reprints: John S. Walsh, MD, Department of Dermatology, Mayo Clinic, 4500 San Pablo Rd, Jacksonville, FL 32224 (e-mail: walsh.john@mayo.edu).

REFERENCES

1. Huilgol SC, Ramnarain N, Carrington P, Leigh IM, Black MM. Cytokeratins in primary cutaneous amyloidosis. *Australas J Dermatol.* 1998;39:81-85.
2. Brownstein MH, Helwig EB. The cutaneous amyloidoses, I: localized forms. *Arch Dermatol.* 1970;102:8-19.
3. Woollons A, Black MM. Nodular localized primary cutaneous amyloidosis: a long-term follow-up study. *Br J Dermatol.* 2001;145:105-109.
4. Inazumi T, Hakuno M, Yamada H, et al. Characterization of the amyloid fibril from primary localized cutaneous nodular amyloidosis associated with Sjogren's syndrome. *Dermatology.* 1994;189:125-128.
5. Hagari Y, Mihara M, Hagari S. Nodular localized cutaneous amyloidosis. *Br J Dermatol.* 1996;135:630-633.
6. Hagari Y, Mihara M, Konohana I, Ueki H, Yamamoto O, Koizumi H. Nodular localized cutaneous amyloidosis. *Br J Dermatol.* 1998;138:652-654.
7. Setoguchi M, Hoshii Y, Kawano H, Ishihara T. Analysis of plasma cell clonality in localized AL amyloidosis. *Amyloid.* 2000;7:41-45.
8. Pepys MB, Dyck RF, de Beer FC, Skinner M, Cohen AS. Binding of serum amyloid P component (SAP) by amyloid fibrils. *Clin Exp Immunol.* 1979;38:284-293.
9. Hawkins PN, Lavender JP, Pepys MB. Evaluation of systemic amyloidosis by scintigraphy with 123I-labeled serum amyloid P component. *N Engl J Med.* 1990; 323:508-513.

©2003 American Medical Association. All rights reserved.
Downloaded From: http://archderm.jamanetwork.com/ on 05/22/2013