OBSERVATION

Nephrogenic Fibrosing Dermopathy With Systemic Involvement

William W. Ting, MD, MBA; Mary Seabury Stone, MD; Kathi C. Madison, MD; Kevin Kurtz, MD

Background: There is a growing literature regarding sclerotic and panniculitic cutaneous conditions seen in patients with end-stage renal disease (eg, calciphylaxis and soft tissue calcification). Nephrogenic fibrosing dermopathy (NFD) is a recent designation to describe cutaneous findings in patients with end-stage renal disease who developed sclerotic plaques with scleromyxedema-like histologic features. Soft tissue calcification is rare in patients with NFD and systemic involvement has not been reported.

Observations: We describe a patient with end-stage renal disease who developed diffuse indurated woody plaques consistent with NFD in association with soft tissue calcification with catastrophic sequelae. A deep excisional biopsy specimen from the patient revealed thickened collagen bundles in the reticular dermis, plump bipolar spindle cells, and increased mucin. Focally, there were zones of calcium deposition in dermal collagen without vessel calcification. Autopsy of the patient revealed extensive fibrosis and calcification of the diaphragm, psoas muscle, renal tubules, and rete testes. The patient died 11 months after developing NFD.

Conclusion: A subset of patients with NFD may have significant systemic involvement.

Arch Dermatol. 2003;139:903-906

Calciphylaxis and soft tissue calcification have long been associated with end-stage renal disease (ESRD).[1,2] Nephrogenic fibrosing dermopathy (NFD) is a recently recognized syndrome in patients with ESRD manifested by sclerotic plaques with scleromyxedema-like histologic features. This disorder was first reported as scleromyxedema-like cutaneous disease[3] and then renamed nephrogenic fibrosing dermopathy by Cowper and colleagues.[4] Systemic involvement has not been described in NFD.[3,4] In fact, there have been no deaths in the 49 patients with NFD reported to the Centers for Disease Control and Prevention (CDC).[5]

We describe a patient with ESRD who rapidly developed clinically and histologically typical NFD associated with prominent soft tissue calcification. Autopsy findings suggest that systemic involvement can occur in NFD.

From the Departments of Dermatology (Drs Ting, Stone, and Madison) and Pathology (Drs Stone and Kurtz), University of Iowa College of Medicine, Iowa City. *The authors have no relevant financial interest in this article.*

REPORT OF A CASE

HISTORY

A 60-year-old white man with ESRD secondary to hypertension developed the acute onset of painful erythematous indurated plaques on the posterior arms, buttocks, and posterior thighs 6 days after vascular rejection of a cadaveric kidney transplant due to renal vein thrombosis. One day prior to the cutaneous eruption, the patient developed hypovolemic shock and respiratory failure and was successfully resuscitated with pressor medications, 10 U of red blood cells, and intravenous fluids free of calcium. His medications at the onset of the skin findings included erythropoietin (Epogen; Amgen Inc, Thousand Oaks, Calif) (10 000 U 3 times a week administered with each hemodialysis), lansoprazole (Prevacid; TAP Pharmaceuticals Inc, Lake Forest, Ill), prednisone, iron, ascorbic acid, and topical nystatin. An antithrombin III (58%; reference range, 69%-132%) and factor II deficiency (36%; reference range, 50%-200%) coagulopathy was identified as the likely cause of the vascular complication. He had negative findings for antinuclear and anticardiolipin antibodies and had normal findings for proteins C and S. Radiographs of the upper extremities showed no evidence of calcification. Pertinent laboratory data included calcium, 8.7 mg/dL (2.2 mmol/L) (reference range, 8.5-10.5 mg/dL

For editorial comment see page 928

©2003 American Medical Association. All rights reserved.
Downloaded From: http://archderm.jamanetwork.com/ on 05/19/2013

Figure 1. Sclerotic plaque with calcinosis on the back (A) and front (B) arm of the patient.

[2.1-2.6 mmol/L]); phosphorus, 12.2 mg/dL (3.9 mmol/L) (reference range, 2.5-4.5 mg/dL [0.8-1.4 mmol/L]); calcium-phosphorus index, 106; and parathyroid hormone, 146 pg/mL (reference range, 10-65 pg/mL).

PHYSICAL EXAMINATION

Physical examination revealed a frail, fatigued white man who was not in acute distress. There were several very large, painful, firm, indurated plaques with irregular borders and peau d'orange textural changes along the dependent areas of posterior arms, buttocks, back, and posterior thighs with markedly decreased range of motion of all extremities (**Figure 1**). There was no ulceration.

CLINICAL COURSE

Deep incisional skin biopsy findings were consistent with NFD (see "Pathology" section). Despite a series of attempts to treat his condition with trials of hydroxychloroquine, prednisone, cyclosporine, psoralen–UV-A, and extracorporeal photopheresis in addition to zero-calcium dialysis, sevelamer hydrochloride (Renagel; Gel-Tex Pharmaceuticals, Inc, Waltham, Mass), and physical therapy, the patient had progressive cutaneous disease (even with normalized serum calcium level) with disabling limitation of movement, severe shortness of breath, and complete inability to perform the activities of daily living. Parathyroidectomy was considered but not pursued given the patient's frail medical condition and with respect to family request. Although the patient remained anuric throughout the clinical course, his renal function remained stable while receiving hemodialysis 3 times weekly. Hemodialysis was administered via a high-flux F70 dialyzer with central water treatment system (F70 is a biocompatible polysulfone membrane). Because of the intolerable morbidity of his disease, he chose to discontinue dialysis, and he died 11 months after the onset of NFD.

PATHOLOGY

A deep incisional skin biopsy specimen from the patient revealed thickened collagen bundles in the reticular

©2003 American Medical Association. All rights reserved.
Downloaded From: http://archderm.jamanetwork.com/ on 05/19/2013

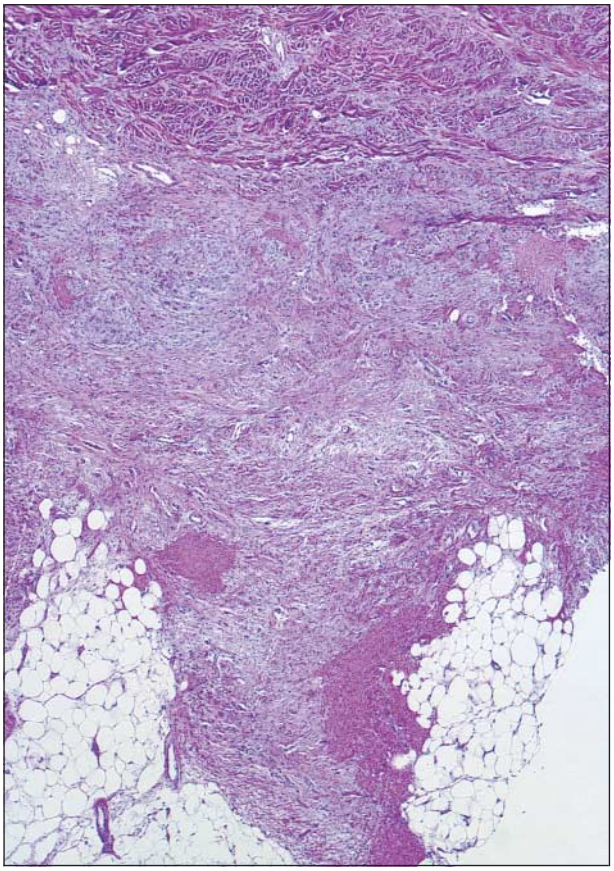

Figure 2. Thickened collagen and spindle cells are seen in the reticular dermis and extending into the underlying subcutis (hematoxylin-eosin, original magnification ×4).

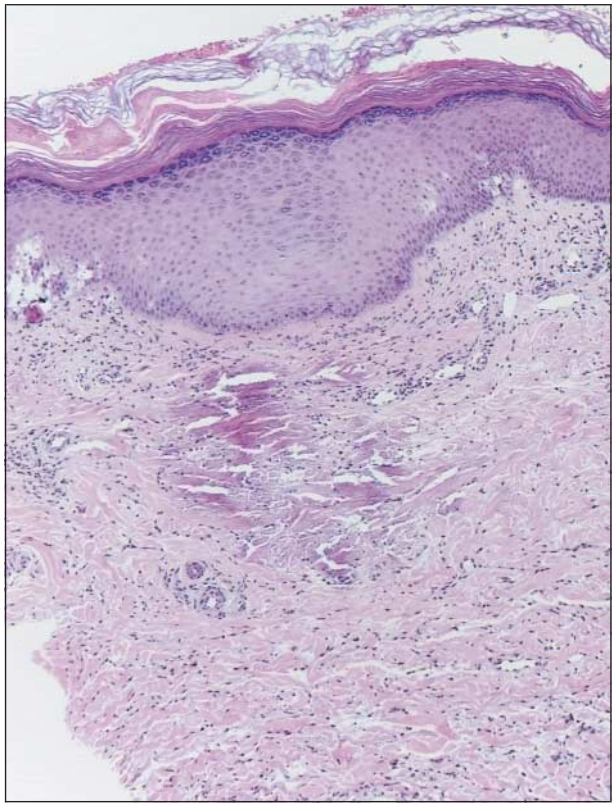

Figure 3. Soft tissue calcification without mural calcification of upper dermal collagen (hematoxylin-eosin, original magnification ×10).

dermis with interspersed plump spindle cells (**Figure 2**). The fibrous proliferation extended into the underlying subcutis, fascia, and skeletal muscles as thick fibrous bands. Dermal mucin was mildly increased. Focally, there were large zones of calcium deposition within the collagen bundles without vessel calcification (**Figure 3**).

An autopsy was performed. In addition to the cutaneous findings described previously, fibrosis and calcium deposition were present systemically. Gross examination of the internal organs demonstrated an indurated, gritty diaphragm. Microscopically, most of the diaphragm was replaced by fibrous tissue with extensive vascular and extravascular calcium deposition (**Figure 4**). The diaphragm was also infiltrated by numerous CD68-positive multinucleated cells. Fibrosis and calcification were present in the psoas muscle, and excess collagen deposition without calcification was identified in the skeletal muscle of the proximal esophagus. Although grossly normal, the myocardium of the left ventricle contained a calcified vessel surrounded by fibrosis. Focal intimal calcifications were also present in the vessels of the lungs and kidneys. Histologic sections of the rete testis and renal tubules showed extravascular calcium deposits. Other findings at autopsy included hyperplasia of 3 parathyroid glands, atherosclerosis, and markedly atrophic kidneys.

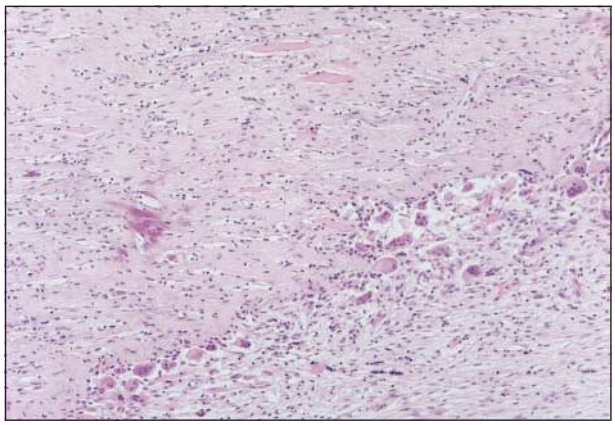

Figure 4. The normal muscle of the diaphragm has been replaced by fibroblasts and collagen with marked calcium deposition (hematoxylin-eosin, original magnification ×40).

COMMENT

Our patient with ESRD presented with diffuse indurated woody plaques, initially accentuated on dependent areas. Skin biopsy specimens showed focal dermal calcification and extensive fibrosis with increased dermal mucin histologically reminiscent of scleromyxedema. The patient had an elevated calcium-phosphate index and the skin changes were preceded by vascular rejection of a cadaveric renal transplant. Unlike the cohort of 14 patients described by Cowper et al,[3,4] our patient had systemic involvement. Indeed, our patient died within

©2003 American Medical Association. All rights reserved.
Downloaded From: http://archderm.jamanetwork.com/ on 05/19/2013

11 months of the onset of NFD, while there have been no deaths in the 49 patients with NFD who have been reported to the CDC.[5] Although absence of systemic involvement was noted to be one of the key features of NFD by Cowper et al,[4] we believe that it may be worthwhile to reconsider the definition of NFD in light of our patient who had NFD with definite systemic involvement. The presence of fibrosis and CD68-positive multinucleated cells in the diaphragm strongly support a relationship between the patient's systemic disease and NFD. The skin of the patients described by Cowper et al[4] showed similar CD68-positive multinucleated cells. Whether NFD with associated soft tissue calcification represents a subset of NFD patients with more severe disease is a question that awaits further study of this disorder.

The rarity of NFD, its recent recognition, and the reported clustering of cases make a toxic and/or an infectious etiology an attractive theory for pathogenesis. Both the toxic oil syndrome and eosinophilia-myalgia syndrome demonstrate that toxins can cause cutaneous fibrosing disorders.[6] The CDC has begun collecting cases of NFD in an attempt to determine the underlying etiology. Such an understanding will hopefully lead to prevention and/or improved management of a devastating disorder for which treatment has been ineffective to date.

Accepted for publication November 5, 2002.

This study was supported in part by funds from the Department of Dermatology, University of Iowa Health Care, Iowa City.

The content of this article was presented as a poster at the European Academy of Dermatology and Venereology, Prague, Czech Republic, October 2-6, 2002.

We would like to thank the patient's family members for their support of our efforts to improve understanding of this disorder. Robert C. Albright, DO, and Marian T. McEvoy, MD, Mayo Clinic, Rochester, Minn, provided expert clinical care to the patient described in the present article.

Reprints not available from the authors.

REFERENCES

1. Walsh JS, Fairley JA. Calcifying disorders of the skin. *J Am Acad Dermatol.* 1995; 33:693-706.
2. Robinson-Bostom L, DiGiovanna JJ. Cutaneous manifestations of end-stage renal disease. *J Am Acad Dermatol.* 2000;43:975-986.
3. Cowper SE, Robin HS, Steinberg SM, Su LD, Gupta S, LeBoit PE. Scleromyxoedema-like cutaneous diseases in renal-dialysis patients. *Lancet.* 2000; 356:1000-1001.
4. Cowper SE, Su LD, Bhawan J, Robin HS, Leboit PE. Nephrogenic fibrosing dermopathy. *Am J Dermatopathol.* 2001;23:383-393.
5. Cowper S, LeBoit P, Su L, et al. Fibrosing skin condition among patients with renal disease—United States and Europe, 1997-2002. *MMWR Morb Mortal Wkly Rep.* 2002;51:25-26.
6. Diggle GE. The toxic oil syndrome: 20 years on. *Int J Clin Pract.* 2001;55:371-375.

News and Notes

The Dermatopathology Update Course will be offered by the Harvard Medical School, Department of Continuing Education, September 10-13, 2003, at the Fairmont Hotel, Boston, Mass. The directors are Thomas J. Flotte, MD; Philip H. McKee, MD, FRCPath; Martin C. Mihm Jr, MD, FACP; Steven R. Tahan, MD; and Artur Zembowicz, MD, PhD.

The objective of this year's course is to provide an in-depth review and update on selected topics in dermatopathology, focusing on nonneoplastic disease and melanocytic lesions. The course has been redesigned and is specifically aimed at practicing pathologists, dermatopathologists, and dermatologists. The program is also suitable for senior residents and fellows preparing for board-certification examinations. Detailed course information and registration information is available online at http://www.cme.hms.harvard.edu or by telephone at (617) 384-8600.

©2003 American Medical Association. All rights reserved.
Downloaded From: http://archderm.jamanetwork.com/ on 05/19/2013